



**E Journal
of Cardiovascular
Medicine**

| Volume **4** | Issue **3** |

| July-September **2016** |

www.ejcvsmmed.org

E Journal of Cardiovascular Medicine

Aortic surgery cost and outcome at teaching vs. non-teaching hospitals

Azam Jan, Naseer Ahmed, Mumtaz Anwar Shah, Somiya Rehman, Alessio Rungtischer, Giuseppe Faggian

Need for hypogastric artery preservation in endovascular repair for aorto - Iliac Aneurysms

*Rocco Giudice, Ottavia Borghese, Raimondo Grossi, Carlo Coscarella,
Giorgio Sbenaglia, Silvana Pirillo, Massimo Danese, Mario Albertucci*

Infective endocarditis after tattooing in adolescent patient with ventricular septal defect

Çetin Alak

E-Journal of Cardiovascular Medicine welcomes scientific contributions in the field of cardiovascular and thoracic surgery - all aspects of surgery of the heart, vessels and the chest in various article types: new ideas, brief communications, work in progress, follow-up studies, original articles, best evidence topics, case reports, reports on unexpected results etc. All manuscripts shall be reviewed by the Editor-in-Chief, Associate Editors, Invited Referees and a Statistician when appropriate. If accepted, articles will be posted online and opened up for discussion. Acceptance criteria are based on the originality, significance, and validity of the material presented.

All material to be considered for publication in E-Journal of Cardiovascular Medicine should be submitted in electronic form via the journal's online submission system. (<http://my.ejmanager.com/ejcm/>)

A cover letter should be enclosed to all new manuscripts (to be filled in online), specifying the name of the journal and the type of paper, and including the following statements:

- The manuscript should not be previously published in print or electronic form and is not under consideration by another publication.
- All authors should contribute to the content of the article.
- All authors should read and approve the submission of the manuscript to ICVTS.
- Subject to acceptance, authors will sign an exclusive license to publish.
- No ethical problem or conflict of interest should exist.

If your first language is not English, we recommend that you consult an English language editing service to ensure that the academic content of your paper is fully understood by journal editors and reviewers. Language editing does not guarantee that your manuscript will be accepted for publication.

Manuscripts should be prepared using a word-processing package (save in .doc, .docx or .rtf format). The font type and font size should preferably be Arial or Times New Roman 11 points. The manuscript should be double-spaced and should include line and page numbers. The lines of the reference list do not need to be numbered; include a section break before.

Manuscripts should be organized as follows:

(a) Title page; (b) Abstract and Key words; (c) Text with the following sections (not applicable for article types with unstructured abstracts): Introduction, Materials and Methods, Results, Discussion, Acknowledgement (optional), Funding statement, Conflict of interest statement, (d) Figure (and Video) legends; (e) Tables; (f) References.

Title page (1st page): Title: should be brief and descriptive (100 characters) - no abbreviations are allowed, even if well known.

Authors: list all authors by full first name, initial of or full middle name and family name. Qualifications are not required. Ensure the author names correspond (in spelling and order of appearance) with the metadata of the system

Institution(s): include the name of all institutions with the location

(department, institution, city, country) to which the work should be attributed (in English). Use superscript numbers to connect authors and their department or institution.

Corresponding author: The full name, full postal address, telephone/fax numbers and the e-mail address should be typed at the bottom of the title page.

Meeting presentation: If the manuscript was (or will be) presented at a meeting, include the meeting name, venue, and the date on which it was (or will be) read; also indicate if you have submitted an Abstract of this manuscript for the EACTS or ESTS annual meeting and whether it has been accepted (if known).

Word count: The total number of words of the whole article (including title page, abstract, main text, legends, tables and references) must be specified on the title page.

Abstract (2nd page): An abstract should be a concise summary of the manuscript. Reference citations are not allowed. The abstract should be factual and free of abbreviations, except for SI units of measurement.

Keywords: Following the abstract, 3-6 keywords should be given for subject indexing.

Introduction: Should state the purpose of the investigation and give a short review of pertinent literature.

Materials and methods: Should be described in detail with appropriate information about patients or experimental animals. Use of abbreviations renders the text difficult to read; abbreviations should be limited to SI units of measurement and to those most commonly used, e.g. VSD, ASD, CABG (abbreviations should not be included in headings and extensions should be included at first mention).

Results: Results should be reported concisely and regarded as an important part of the manuscript. They should be presented either in tables and figures, and briefly commented on in the text, or in the text alone. Repetition of results should be avoided!

Discussion: The discussion is an interpretation of the results and their significance with reference to pertinent work by other authors. It should be clear and concise.

Acknowledgement: Acknowledgements and details of non-financial support must be included at the end of the text before the references. Personal acknowledgements should precede those of institutions or agencies.

Tables: All tables must be included in the manuscript file, should start on separate pages and be accompanied by a title, and footnotes where necessary. The tables should be numbered consecutively using Arabic numerals. Units in which results are expressed should be given in parentheses at the top of each column and not repeated in each line of the table.

References: Authors are responsible for checking the accuracy of all references. If you use EndNote or Reference Manager to facilitate referencing citations (not required for submission), this journal's style is available for use. References should be numbered in order of appearance in the text (in Arabic numerals in parentheses) and must be listed numerically in the reference list. Journal titles and author initials should be properly abbreviated and punctuated.

Editor-in-Chief

Prof. Öztekin Oto

FESC, FACC / President, Heart and Health Foundation of Turkey / Izmir / Turkey

Asistant Editors

Prof. Ali Kutsal

*Sami Ulus Children Hospital Department of
Cardiovascular Sugery / Ankara / Turkey*

Prof. Erdem Silistreli

*Dokuz Eylül University, Department of Cardiovascular
Sugery / Izmir / Turkey*

Prof. Bektaş Battaloğlu

*İnönü University, Department of Cardiovascular Sugery
Malatya / Turkey*

Dr. Onur Saydam

*Karaman State Hospital Cardiovascular Surgery
Karaman / Turkey*

Dr. Emre Doğan

*Trabzon Ahi Evren Cardiovascular Surgery Hospital
Trabzon / Turkey*

Dr. Taylan Adademir

Kartal Koşuyolu Resarch Hospital / Istanbul / Turkey

Owner

© TÜSAV Heart and Health Foundation of Turkey

Administration Office

Şair Eşref Bulvarı, 1402 Sk. No. 2/2 Özbaş Apt.
Alsancak - Izmir / Turkey
Tel: + 90 232 464 19 63 / Fax: +90 232 464 24 70
e-mail: info@oztekinoto.com | info@tksv.org

Publishing Coordinator

Hüseyin Kandemir

huseyin@medikalakademi.com.tr

Publisher

Medikal Akademi Yayıncılık ve Prodüksiyon Tic. Ltd. Sti.
Halaskargazi Cad. No: 172, D: 134 - Şişli / İstanbul
Tel: +90 537 309 29 55, Faks: (0212) 233 90 61
www.medikalakademi.com.tr/hizmetlerimiz

International Scientific Advisory Board

Prof. Harald Kaemmerer

German Heart Centre / Munich / Germany

Prof. Marko Turina

University Hospital of Zurich / Zurich / Switzerland

Prof. Frank W. Selke

*Chief of Cardiothoracic Surgery at Brown Medical School
Rhode Island / USA*

Prof. Joseph E. Bavaria

*Hospital of the University of Pennsylvania
Philadelphia / USA*

Prof. Fausto Pinto

*Director of Lisbon Cardiovascular Institute / Portugal
& President of the European Society of Cardiology*

Prof. Lazar Davidovic

*Belgrade Medical School Cardiovascular Surgery
Belgrade / Serbia*

Prof. Stephan Schueler

*Tyne Freeman Hospital, Department for Cardiothoracic
Surgery Newcastle / United Kingdom*

Prof. Piotr Kasprzak

*University Hospital Regensburg, Director of Vascular
Surgery / Regensburg / Germany*

Prof. Jose Luis Pomar

*Hospital Clinico de Barcelona, Department of
Cardiovascular Sugery / Barcelona / Spain*

Prof. Mohamed Moustafa Abdelaal

*Kafrelsheikh University Hospital, Cardiothoracic surgery and
General Director / Kafr El Sheikh / Egypt*

Assoc. Prof. Barış Akça

*Inonu University School of Medicine, Department of
Cardiovascular Surgery / Malatya / Turkey*

Dr. Rezan Aksoy

*Siyami Ersek Training and Research Hospital,
Cardiovascular Surgery / Istanbul / Turkey*

Dr. Şafak Alpat

*Birmingham Children's Hospital Pediatric Cardiovascular
Surgery / Birmingham / UK*

Dr. Mustafa Aldemir

*Kocatepe University, Department of Cardiovascular
Surgery / Afyon / Turkey*

Dr. Elena Zapata-Arriaza

*Hospital Universitario Virgen del Rocío, Instituto de
biomedicina de Sevilla, Vascular Medicine / Sevilla / Spain*

Dr. Mehmet Atay

*Bakırköy Sadi Konuk Research Hospital, Cardiovascular
Surgery / Istanbul / Turkey*

Assoc. Prof. Hakan Aydın

*Sami Ulus in Ankara Training and Research Hospital,
Cardiovascular Surgery / Ankara / Turkey*

Assoc. Prof. Ahmet Çağrı Aykan

*Ahi Evren University of Health Sciences, Thoracic and
Cardiovascular Surgery / Trabzon / Turkey*

Assoc. Prof. Vedat Bakuy

*Bakırköy Sadi Konuk Training and Research Hospital,
Cardiovascular Surgery / Istanbul / Turkey*

Dr. Stefano Bartoli

*ASL Roma2, Cardiovascular Surgery
Rome / Italy*

Assoc. Prof. Elif Börekçi

*Bozok University Research and Application Hospital,
Internal Medicine / Yozgat / Turkey*

Dr. Tomasa Centella

*Hospital Ramón y Cajal, Cardiovascular Surgery
Madrid / Spain*

Assoc. Prof. Ahmet Çalışkan

*Dicle University School of Medicine, Cardiovascular Surgery
Diyarbakır / Turkey*

Dr. Gökhan Çavuşoğlu

*Ahi Evren University of Health Sciences, Thoracic and
Cardiovascular Surgery, Radiology / Trabzon / Turkey*

Dr. Deniz Çevirme

*Kartal Koşuyolu Research and Education
Hospital, Cardiovascular Surgery / Istanbul / Turkey*

Prof. Ferit Çiçekçioğlu

*Bozok University, Training and Research Hospital,
Cardiovascular Sugery / Yozgat / Turkey*

Assoc. Prof. Ertan Demirdaş

*Bozok University Research and Application Hospital and
Cardiovascular Surgery / Yozgat / Turkey*

Assoc. Prof. Yüksel Dereli

*Necmettin Erbakan University, Meram Midical Faculty
Hospital, Cardiovascular Surgery / Konya / Turkey*

Assist.Prof. İnci Selin Doğan

*Karadeniz Technical University Faculty of Pharmacy
Pharmacology, Medicinal Chemistry / Trabzon / Turkey*

Dr. Vehbi Doğan

*Sami Ulus Training and Research Hospital, Pediatric
Cardiology / Ankara / Turkey*

Dr. Çağrı Düzyol

*Kocaeli Derince Education and Research Hospital
Cardiovascular Surgery / Kocaeli / Turkey*

Assoc. Prof. Hüseyin Ede

*Bozok University, Medical Faculty, Cardiovascular Surgery
Yozgat / Turkey*

Dr. İlker Ertuğrul

*Sami Ulus Training and Research Hospital, Pediatric
Cardiology / Ankara / Turkey*

Prof. Niyazi Görmüş

*Necmettin Erbakan University, Meram Medical Faculty
Hospital, Cardiovascular Surgery / Konya / Turkey*

Assist. Prof. Adem Güler

*Gulhane Military Medical Academy Department of
Cardiovascular Surgery / Ankara / Turkey*

Assoc. Prof. Mustafa Gülgün

*GATA Department of Pediatrics, Division of Pediatric
Cardiology / Ankara / Turkey*

Prof. Usama Ali M. Hamza

*Mansoura University Faculty of Medicine, Cardiothoracic
Surgery, Cardiovascular Surgery / Mansoura / Egypt /*

Dr. James B Hermiller

*St Vincent's Medical Group, Interventional Cardiology
Indianapolis / USA*

Dr. Akihiko Ikeda

*Tsukuba Medical Center Hospital, Cardiovascular
Surgery / Tsukuba / Japan*

Dr. Richard W Issitt

*Great Ormond Street Hospital, Cardiac Surgery -
Pediatric Cardiology / London / UK*

Dr. Mehmet Kalender

*Derince Training and Research Hospital, Cardiovascular
Surgery / Kocaeli / Turkey*

Dr. Ayşegül Karadeniz

*Ahi Evren University of Health Sciences, Thoracic and
Cardiovascular Surgery, Radiobiology / Trabzon / Turkey*

Assoc. Prof. Osman Kayapınar

*Düzce University, Medical Faculty Department of
Cardiology / Düzce / Turkey*

Assoc. Prof. Alper Kepez

*Marmara University Training and Research Hospital Cardiol-
ogy Clinic / Istanbul / Turkey*

Assoc. Prof. Yasir Khan Khan

*Ch. Pervaiz Elahi Institute of Cardiology, Cardiovascular Sur-
gery / Punjab / Pakistan*

Assoc. Prof. Levent Korkmaz

*Ahi Evren University of Health Sciences, Thoracic and
Cardiovascular Surgery / Trabzon / Turkey*

Assoc. Prof. Ulaş Kumbasar

*Hacettepe University Medical School Cardiovascular
Surgery / Ankara / Turkey*

Dr. Redha Lakehal

*Department of heart surgery, EHS Erriadh / Constantine
Algeria*

Dr. Wei-Chieh Lee

*Kaohsiung Chang Gung Memorial Hospital, Cardiology
Kaohsiung City / Taiwan*

Dr. José Luis Serrano Martínez

*University Hospital of Granada, Department of Internal
Medicine / Granada / Spain*

Assoc. Prof. Ümit Mentşe

*Ahi Evren University of Health Sciences, Thoracic and
Cardiovascular Surgery / Trabzon / Turkey*

Dr. Nooredin Mohammadi

*Iran University of Medical Sciences, Cardiology, Demand
for Health Care, Determinants of Health / Tehran / Iran*

Dr. Vinod Namana

*Maimonides Medical Center, Department of Medical
Research / New York / USA*

Dr. Silvio Nocco

Sirai Hospital, Department of Cardiology / Carbonia / Italy

Assoc. Prof. Zeynep Tuğba Özdemir

*Bozok University School of Medicine, Internal Medicine
Yozgat / Turkey*

Dr. Tanıl Özer

*Kartal Koşuyolu Yüksek İhtisas Research and Education
Hospital / İstanbul / Turkey*

Prof. Murat Özeren

*Mersin University Medical School, Cardiovascular
Surgery / Mersin / Turkey*

Assoc. Prof. Emre Özker

*Başkent University School of Medicine, Department of
Cardiovascular Surgery / Ankara / Turkey*

Dr. Abdullah Özyurt

*Mersin Maternity and Children Diseases Hospital, Pediatric
Cardiology / Mersin / Turkey*

Dr. Recep Oktay Peker

*Hacettepe University, Department of Cardiovascular Surgery
Ankara / Turkey*

Dr. Hikmet Sahratov

*Gülhane Education and Research Hospital, Department of
Cardiovascular Surgery / Ankara / Turkey*

Dr. Gonzalo Luis Alonso Salinas

*Marcelo Sanmartín of Hospital Universitario Ramón y Cajal
Madrid / Spain*

Dr. Stefano Salizzoni

*Città della Salute e della Scienza, Cardiac Surgery,
Cardiac Surgery / Turin / Italy*

Dr. Gökhan Sargın

*Adnan Menderes University Medical School, Internal
Medicine / Aydın / Turkey*

Dr. Mustafa Seren

*Ankara 29 Mayıs State Hospital and Cardiovascular
Surgery / Ankara / Turkey*

Prof. Erdem Silistreli

*Dokuz Eylül University, Department of Cardiovascular
Surgery / İzmir / Turkey*

Assoc. Prof. Ömer Tanyeli

*Necmettin Erbakan University, Meram Medical Faculty
Hospital, Cardiovascular Surgery / Konya / Turkey*

Dr. İlker Tekin

*Antalya Medicalpark Hospital, Cardiovascular Surgery
Antalya / Turkey*

Assist. Prof. Dinçer Uysal

*Isparta Süleyman Demirel University, Department of
Cardiovascular Surgery / Isparta / Turkey*

Dr. Olivier Villemain

*IM3C Necker-Enfants Malades, AP-HP, Université Paris
Descartes, Pediatric Cardiology, Radiology / Paris / France*

Dr. Mustafa Esat Yamaç

*Ahi Evren University of Health Sciences, Thoracic and
Cardiovascular Surgery / Trabzon / Turkey*

Assoc. Prof. Ali Ümit Yener

*Canakkale Onsekiz Mart University Medical Faculty,
Department of Cardiovascular Surgery / Çanakkale / Turkey*

Dr. Dilek Yeşilbursa

*Uludağ University, Medical Faculty, Department of
Cardiology / Bursa / Turkey*

Dr. Mustafa Yılmaz

*Sami Ulus Training and Research Hospital, Pediatric
Cardiology / Ankara / Turkey*

| Volume **4** | Issue **2** | July-September **2016** |

Research Articles

Need for hypogastric artery preservation in endovascular repair for aorto - Iliac Aneurysms | 49

Rocco Giudice, Ottavia Borghese, Raimondo Grossi, Carlo Coscarella,
Giorgio Sbenaglia, Silvana Pirillo, Massimo Danese, Mario Albertucci

Aortic surgery cost and outcome at teaching vs. non-teaching hospitals | 56

Azam Jan, Naseer Ahmed, Mumtaz Anwar Shah,
Somiya Rehman, Alessio Rungatscher, Giuseppe Faggian

Case Report

The minimally invasive right vertical infra-axillary lateral minithoracotomy approach for the heart valve surgery: Report of 115 cases | 63

Mahmut Akyıldız, Ahmet Refik Turgut, Taner Şerif Küçükcerit,
Güzin Kaşo, Remzi Tosun, Noyan Temuçin Oğuş

Aortic aneurysm and mitral regurgitation as first manifestations of ankylosing spondilitis | 71

Ertan Demirdaş, Kıvanç Atılğan, Utkan Sevak, Oğuz Taşdemir

Infective endocarditis after tattooing in adolescent patient with ventricular septal defect | 73

Çetin Alak

Need for hypogastric artery preservation in endovascular repair for aorto - Iliac Aneurysms

Rocco Giudice¹, Ottavia Borghese¹, Raimondo Grossi¹, Carlo Coscarella¹, Giorgio Sbenaglia¹, Silvana Pirillo², Massimo Danese¹, Mario Albertucci¹

¹) S. Giovanni - Addolorata Hospital, Vascular and Endovascular Surgery Unit, Rome, Italy

²) S. Giovanni - Addolorata Hospital, Department of Radiology, Rome, Italy

Abstract

Objective: Effective distal sealing in endovascular aorto-iliac aneurysm repair often requires landing in the external iliac artery, thus questioning the fate of the hypogastric artery circulation. Besides simple embolization to prevent a type 2 endoleak, several solutions exist for hypogastric flow preservation, each laden with increasing complexity and/or financial burden. The present study evaluated the rationale of hypogastric artery preservation in this clinical setting.

Methods: From January 1999 to June 2016, 749 patients underwent endovascular repair of abdominal aortic aneurysm. Among these, 112 with aneurysm involving the iliac vessels required consideration for closing one (95) or both (17) hypogastric arteries. One-hundred and three patients were male and 9 were female. The mean age was 75 (52-88). When only one hypogastric artery (with patency of the contralateral) needed sacrifice, the usual practice has been simple embolization with plugs or coils before the endografting. Nevertheless, 4 patients with unilateral iliac involvement, who had an active lifestyle, received a branched endograft for hypogastric preservation. When landing in the external iliac artery was needed bilaterally, in 16 cases one hypogastric artery was embolized and the other one was preserved with branched endografts (N=11), “double barrel” technique (N=3) or hybrid repair using an open bypass from external to internal iliac artery (N=2); in only one patient a bilateral branched endograft was used to preserve both hypogastriacs.

Results: Preservation of the hypogastric artery was achieved in 21 out of the 22 target vessels: one patient, who received a branched endograft, experienced immediate occlusion of the hypogastric stent, without any clinical sequelae. In the early postoperative period none of the 112 patients had symptoms of critical gluteal and/or pelvic visceral ischemia. At a mean follow-up of 48 months (1-152), no further procedures were necessary for proximal and/or distal type I endoleak. All the hypogastric arteries but one, in the 20 patients in whom they were preserved, remained patent. Even though 33% of the patients (37 out of 112) reported mild to moderate gluteal claudication during the first 6 months after the procedure, the symptoms improved progressively, and residual complaints were presented at the 1 year visit or later only in 8% of cases. Moreover, no substantial changes in sexual activity were reported in any case.

Conclusion: From a cost-effectiveness perspective, adjunctive procedures for monolateral hypogastric artery preservation with contralateral patency are not warranted. These techniques should be reserved for the selected few cases when both hypogastric arteries need to be sacrificed, or when there is a peculiar need for their preservation.

Keywords: Aortoiliac aneurysm, Hypogastric artery, Iliac branched device, Endovascular aneurysm repair

Giudice R., Borghese O., Grossi R., Coscarella C., Sbenaglia G., Pirillo S., Danese M., Albertucci M. Need for hypogastric artery preservation in endovascular repair for aorto - Iliac Aneurysms. EJCM 2016; 04 (3): 49-55. Doi: 10.15511/ejcm.16.00349.

Introduction

Effective distal sealing in endovascular aorto-iliac aneurysm repair (EVAR) often requires landing in the external iliac artery, thus questioning the fate of the hypogastric artery (HA) circulation.^[1] Simple hypogastric embolization is generally used to prevent a type 2 endoleak.^[2, 3] Nevertheless, preservation of the internal iliac flow is important to avoid ischemic complications after EVAR, particularly in patients with previous procedures or potential additional future interventions.^[4, 5] Indeed, the sacrifice of the HA carries a non-negligible rate of complications, which may include buttock claudication, sexual dysfunction, ischemic colitis, spinal cord ischemia, as well as buttock and scrotal necrosis^[2, 3, 6, 7] Buttock claudication may improve over time, but up to 15% of the patients remain symptomatic.

In order to reduce the incidence of complications and the disability level, it is advisable to preserve the flow in at least one of the internal iliac arteries, taking advantage of the extensive collateral network in the pelvis.^[2, 3, 6, 7] Several solutions exist for hypogastric flow preservation, such as the bell-bottom technique, hypogastric transposition/bypass, the “double barrel” technique, and the use of dedicated branched endografts, each laden with increasing complexity and/or financial burden.^[3, 6, 8-16] The present study evaluated the rationale of HA preservation in this clinical setting.

Materials and Methods

From January 1999 to June 2016, 749 patients underwent EVAR at our Institution. Among these, we retrospectively reviewed the data of 112 patients (103 males, 9 female), with a median age of 75 years (range 52-88 yrs), who received an endovascular treatment for an aneurysm involving the iliac vessels. Demographics, clinical and radiological information were extracted from prospectively maintained computed databases and from hospital records when needed. Comorbid conditions are outlined in **Table 1**.

The endovascular approach was chosen based on anatomical characteristics and the presence of significant comorbidities. Indication for treatment was the pres-

ence of an abdominal aortic aneurysm (AAA) >50mm associated with dilated common iliac arteries (>25mm) precluding an effective distal sealing, or the presence of an isolated common iliac artery aneurysm greater than 35mm on one or both sides. In this scenario, to achieve a good distal sealing, endograft landing into the external iliac artery was required in 95 patients on one side and in 17 patients on both sides. The preoperative imaging protocol included contrast-enhanced computed tomography (CT) in all patients. A vascular dedicated digital workstation has been used for CT-scan images analysis since 2007 (Aycan Osirix PRO Workstation, Aycan Inc, Wuerzburg, Germany).

All the procedures were carried out in the operative room with the aid of a C-arm equipment, under local or general anesthesia, as appropriate. When only one hypogastric artery (with patency of the contralateral) needed sacrifice, the usual practice was simple embolization at its origin with plugs or coils before deploying the endograft (91 patients). Nevertheless, in this group of unilateral iliac involvement, in 4 cases the HA was preserved using an iliac branched device (IBD), based on patient young age and active lifestyle (**Table 2**). When landing in the external iliac artery was needed

Table 1. Demographics and comorbid conditions in 112 patients

	N	%
Total	112	100
Males	103	92
Females	9	8
CAD*	60	54
Hypertension	91	81
COPD**	21	19
Smoking	93	83
Diabetes	24	21
*Coronary Artery Disease, **Chronic Obstructive Pulmonary Disease		

bilaterally, in 16 cases one HA was embolized and the other one was preserved with different techniques, according to the period considered. In the first phase of the experience, a hybrid repair with open prosthetic bypass from the external to the internal iliac artery was adopted to preserve hypogastric flow in 2 cases. Later, deployment of parallel grafts, one for the internal and one for the external iliac artery (the so-called “double barrel” technique) was used in 3 patients (**Figure 1**). In the last years, with the availability of dedicated branched endografts for hypogastric preservation, our policy has been to implant an IBD on one side plus contralateral hypogastric embolization (11 patients) (**Figure 2**). In only one patient we decided to preserve both hypogastries implanting a bilateral IBD: he was a 52 years-old man with an aorto-iliac aneurysm involving both iliac arteries, who specifically asked for endovascular repair to avoid any possible complication affecting his sexual activity (**Tabel 2**) (**Figure 3**).

As far as the embolization technique is concerned, our strategy is to deploy the occluder (Amplatzer, AGA Medical Corp, Plymouth, MN, USA) or the coils as proximal as possible in the main trunk of the HA, to

better allow for an effective collateral circulation. For aneurysms involving the HA, its primary branches are embolized by means of coils. After hypogastric occlusion, the endograft is deployed down to the external iliac artery during the same operation or few days later in case of staged procedures.

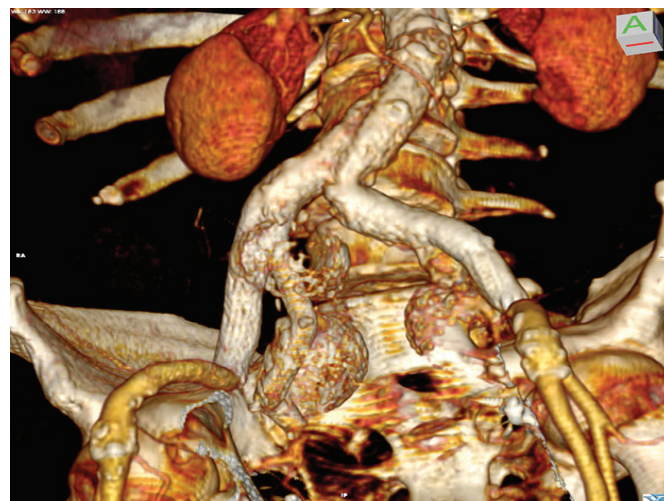In the 3 cases treated with the “double barrel” technique, the Gore Excluder platform (W.L. Gore and Associates, Flagstaff, AZ, USA) was used. Once the bifurcated endograft was in position, two parallel covered stents were deployed, one into the external iliac artery (through the ipsilateral femoral access) and one into the HA through a brachial approach. For the external iliac artery a standard Gore Excluder limb was used, whereas for the HA the covered stent of choice was the Gore Viabahn.

Regarding the 17 IBDs used in our experience, in 5 patients we implanted the Zenith branch device (Cook, Bloomington, IN, USA) with the adjunct of a bridging covered stent (Advanta, Atrium Medical, Hudson, NH, USA or Fluency, C.R., Bard Peripheral Vascular Inc., Murray Hill, NJ, USA) to land and seal into the HA. In the remaining 12 cases, the Gore Excluder branch device (W.L. Gore and Associates, Flagstaff, AZ, USA) was used, which includes a dedicated additional covered stent to bridge to the HA.

Table 2. Technical Details.

Distal Sealing in EIA*	N
One side	95
Simple HA** embolization	91
HA preservation with IBD***	4
Both sides	17
HA embolization on one side + preservation of the contralateral one	16
EIA to HA bypass	2
“Double barrel” technique	3
IBD implant	11
Bilateral HA preservation with 2 IBD	1
*EIA: External Iliac Artery - **HA: Hypogastric Artery - ***IBD: Iliac Branched Device	

Figure 1. Volume Rendering CT-scan reconstruction, showing the “double barrel” technique for the preservation of the right hypogastric artery plus embolization of the left hypogastric artery.



Postoperatively, all patients underwent clinical examination in order to detect symptoms of buttock claudication, skin or muscle necrosis, ischemic colitis, and neurological deficits. Follow-up included clinical evaluation plus imaging with Duplex scan and/or CT scan at 1 month, 6 months and 12 months after the intervention, and yearly thereafter. The persistence of buttock claudication was particularly investigated. Also sexual function was evaluated by questioning all male patients preoperatively as well as after the intervention in the follow-up.

Results

Technical success, defined as the absence of a graft-related endoleak at the end of the procedure, was obtained in all the 112 patients who received an endovascular treatment for an aorto-iliac aneurysm. For patients who underwent hypogastric preservation procedures, the overall procedural success rate in maintaining the patency of the HA with an effective sealing was 95,4% (21 patent HA out of the 22 target vessels). Indeed, one patient, treated with plug embolization on one side and a Cook Zenith IBD on the contralateral one, experienced immediate occlusion of the hypogastric stent that was detected on the completion angiogram at the end

of the procedure, with failed attempt of recanalization. Nevertheless, the patient did not experience severe clinical sequelae but only a mild buttock claudication persistent in the follow-up.

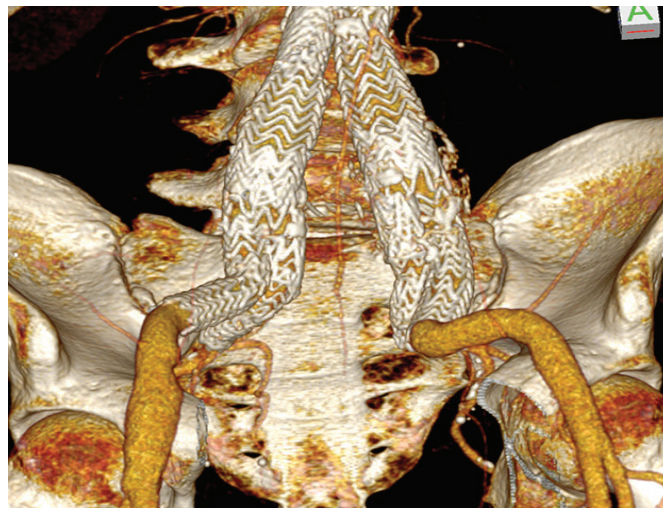
There were no perioperative deaths. In the early postoperative period, none of the 112 patients had symptoms of critical gluteal and/or pelvic visceral ischemia, buttock necrosis, ischemic colitis, or neurologic deficits (**Table 3**).

At a mean follow-up of 48 months (range 1-152), no further procedures were necessary for type I or type III endoleak. Fourteen type II endoleaks were detected at the 1 month post-operative CT-scan: among these, two patients required inferior mesenteric artery embolization for a persistent type II endoleak with aneurysm growth, respectively 18 and 31 months after the EVAR procedure. No aneurysm rupture occurred in the follow-up. All the successfully preserved hypogastric arteries but one remained patent during the follow-up (20 out of 21, 95,2%). One patient treated with the “double barrel” technique on one side and embolization on the contralateral one, showed occlusion of the hypogastric stent at the CT scan 1 year after the operation, without any symptoms.

Figure 2. Volume Rendering CT-scan reconstruction after preservation of the right hypogastric artery with an iliac branched device, associated with embolization of the left hypogastric by means of two occluder plugs.

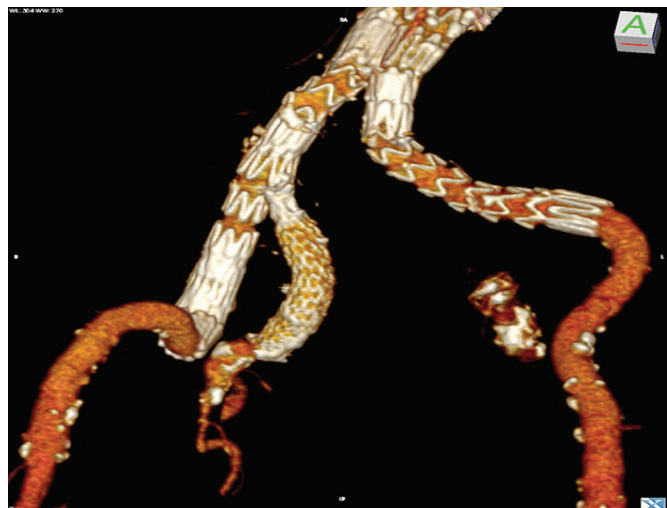

Figure 3. Volume Rendering CT-scan reconstruction, showing bilateral implant of an iliac branched device for preservation of both hypogastric arteries.



Even though 33% of the patients (37 out of 112) reported mild to moderate gluteal claudication during the first 6 months after the procedure, the symptoms improved progressively, and residual complaints were presented at the 1 year visit or later only in 9 cases (8%). In all these patients, symptoms occurred on the side of HA embolization. No patient with two patent HA referred symptoms of buttock claudication.

Moreover, no substantial changes in sexual activity were reported in any case.

Discussion

Effective distal sealing in endovascular repair of abdominal aortic aneurysm may be impaired by the presence of concomitant iliac aneurysmal disease.^[1] This is the case of up to 30% of patients or more, and, particularly in the first phase of the endovascular era, it represented a consistent limiting factor for this technology.^[3] In case of aortoiliac aneurysms extending down to the iliac bifurcation or involving the hypogastric arteries,

distal landing into the external iliac artery is required, thus impacting on pelvic circulation.^[1-3, 5, 6] Indeed, the usual policy is to embolize the HA to prevent a retrograde reperfusion of the aneurysmal sac. Although unilateral hypogastric occlusion is considered a relatively safe procedure, significant post-operative complications may occur, such as buttock claudication, skin/muscle necrosis, ischemic colitis, paraplegia and impotence.^[2, 4, 5] The rate of these adverse events and their severity is higher in case of bilateral occlusion, although not all the authors agree with this statement.^[3] Indeed, the severity of symptoms following the sacrifice of one or both internal iliac arteries is strictly depending on the collateral arterial supply and it is likely that younger and more active patients would experience higher risk of buttock claudication after hypogastric occlusion.^[5, 6, 9, 14, 17] That's why it is generally agreed that effort should be made to preserve at least one hypogastric artery in almost all patients, in order to prevent the risk of life-threatening postoperative ischemic complications.^[3, 18] Attempts at maintaining the flow in both hypogastric arteries are justified only in selected cases, based on patient's young age and in the presence of a real active lifestyle, to limit the possibility of functional disabilities after the operation (such as buttock claudication or sexual function impairment) that clearly assume more clinical relevance in this subset of population.^[16] This is the case of the 4 patients in our experience with unilateral iliac involvement, in whom hypogastric preservation was adopted instead of simple embolization, or the case of the 52 years-old patient described above with bilateral iliac disease, where the implant of 2 IBD was carried out aimed at revascularizing both HA, so preventing possible sexual dysfunction.

When HA sacrifice is planned, its embolization prior to endograft deployment (instead of simple graft coverage) is usually suggested to avoid a type II endoleak from retrograde flow into the aneurysmal sac.^[2, 6, 19] There is general consensus on the opportunity to place the occluder or the coils as proximal as possible, to not interfere with the collateral circulation.^[18, 19] Farahmand et al. 2 reported a higher risk of symptoms in patients in whom coils are deployed into distal ramifications of the HA: this is the case of a not well conducted emboliza-

Table 3. Peri-operative results (30 days).

	N	%
Mortality	0	0
Aneurysm rupture	0	0
Endoleak Type I and III	0	0
Endoleak Type I	14	12
HA* preservation success	21 out of 22 attempted	95
Buttock necrosis	0	0
Buttock claudication	37	33
Ischemic colitis	0	0
Paraparesis / paraplegia	0	0
New onset impotence	0	0
<i>*HA: Hypogastric Artery</i>		

tion procedure, or the case of an aneurysm involving the HA, when embolization of the distal branches is the only option to prevent a retrograde endoleak.

When HA preservation is considered, several techniques have been described. Hybrid procedures with surgical bypass or transposition have been substantially abandoned in the last decade, in favour of a total endovascular approach.^[3, 5, 6, 8-11, 14-16] Different off-label endoluminal techniques using commercially available devices have been proposed, among which the most relevant is the “double-barrel” intervention first described by Lobato.^[13] In our series, we treated 3 patients with this procedure, with an immediate technical success in hypogastric preservation of 100% and a HA patency in the follow-up of 67% (2 out of 3). Nevertheless, considering the present availability of dedicated endografts for HA preservation, we now reserve this procedure only for patients who don’t meet the anatomical requirements for an IBD.

Indeed, the introduction on the market of branched endografts, with the possibility of maintaining an antegrade flow in the HA, significantly changed the scenario in endovascular treatment of aortoiliac aneurysms. Despite the apparent higher complexity of this procedure compared to simple HA embolization, a total endovascular solution with respect of pre-existing pelvic circulation is appealing. Several reports demonstrated the feasibility of this technique, with a high success rate in terms of aneurysm exclusion and HA preservation.^[2, 3, 6, 8-14] In our series, we experienced only one intraoperative failure with early hypogastric stent occlusion, accounting for a technical success of 94,1% (16 out of 17 IBD implanted). All the hypogastric stents remained patent in the follow-up, with no evidence of graft-related endoleaks.

From a technical point of view, we didn’t experience any significant difference between the two IBD models we used, although our preference in the last period goes to the Gore Excluder platform, which offers a dedicated bridging covered stent to land into the HA. From

an economical perspective, the cost-effectiveness of branched devices is open to question: it has been shown that the IBD technique carries an increased operative cost compared to simple HA embolization of approximately 6.000,00 euros, and this confirms the need for careful patient selection.^[20]

It is worth of notice that, with our policy of preserving at least one HA, we didn’t report any severe post-operative ischemic complication (mesenteric or spinal cord infarcts, buttock necrosis). Moreover, considering the relative high median age of our patients, there were no complaints of significant sexual dysfunction compared to the preoperative status. Despite the high incidence of buttock claudication (33%) after ipsilateral HA occlusion, most of the patients spontaneously recovered in the first postoperative year, accounting for residual symptoms in less than 10% of cases. This is the main reason for which we reserve procedures aimed at maintaining HA circulation on both sides only in selected cases of relatively young patients with an active lifestyle.

Conclusion

Considering the relative low risk of complication after unilateral HA interruption when the contralateral one is patent, simple HA embolization with stent graft extension down to the external iliac artery represents in our experience the treatment of choice in EVAR for aortoiliac aneurysms. Techniques for preserving HA flow should be reserved for cases when both hypogastric arteries need to be sacrificed (preserving on one side and embolizing on the contralateral one) or in the presence of a relatively young patient, whose lifestyle could be severely impaired by buttock claudication or sexual dysfunction: in such a patient, in case of bilateral iliac aneurysmal disease, the implant of an IBD on both sides may be worth of consideration.

Funding Statement: *This work received no specific grant from any funding agency in the public, commercial, or not-for-profit sectors.*

References

1. Parlani G, Zannetti S, Verzini F, De Rango P, Carlini G, Lenti M and Cao P. Does the Presence of an Iliac Aneurysm Affect Outcome of Endoluminal AAA Repair? An Analysis of 336 Cases. *Eur J Vasc Endovasc Surg* 2002;24:134-138.
2. Farahmand P, Becquemin JP, Desgranges P, Allaire E, Marzelle J, Roudot, Thoraval F. Is hypogastric artery embolization during endovascular aortoiliac aneurysm repair (EVAR) innocuous and useful? *Eur J Vasc Endovasc Surg* 2008;35:429-435.
3. Karthikesalingam A, Hinchliffe RJ, Holt PJ, Boyle JR, Loftus IM, Thompson MM. Endovascular aneurysm repair with preservation of the internal iliac artery using the iliac branch graft device. *Eur J Vasc Endovasc Surg*. 2010; 39(3):285-294.
4. Wyers MC, Schermerhorn ML, Fillinger MF, Powell RJ, Rzucidlo EM, Walsh DB, Zwolak RM, Cronenwett JL. Internal iliac occlusion without coil embolization during endovascular abdominal aortic aneurysm repair. *J Vasc Surg* 2002; 36(6):1138-1145.
5. Tefera G, Turnipseed WD, Carr SC, Pulfer KA, Hoch JR, Acher CW. Is coil embolization of hypogastric artery necessary during endovascular treatment of aortoiliac aneurysms? *Ann Vasc Surg*. 2004;18(2):143-146.
6. Haulon S, Greenberg RK, Pfaff K, Francis C, Koussa M, West K. Branched grafting for aortoiliac aneurysms. *Eur J Vasc Endovasc Surg* 2007; 33(5):567-574.
7. Jean Baptiste E, Brizzi S, Bartoli MA, Sadaghianloo N, Baqué J, Magnan PE, Hassen Khodja R. Pelvic ischemia and QoL scores after interventional occlusion of the hypogastric artery in patients undergoing EVAR. *J Vasc Surg* 2014; 60(1):40-49.
8. Parlani G, Verzini F, De Rango P, Brambilla D, Coscarella C, Ferrer C, Cao. Long term results of iliac aneurysm repair with iliac branched endograft: a 5 year experience on 100 consecutive cases. *Eur J Vasc Endovasc Surg* 2012;43:287-292.
9. Ziegler P, Avgerinos ED, Umscheid T, Perdikides T, Erz K and Stelter WJ. Branched iliac bifurcation: 6 Years experience with endovascular preservation of internal iliac artery flow. *J Vasc Surg* 2007;46:204-210.
10. Greenberg RK, West K, Pfaff K, Foster J, Skender D, Haulon S, et al. Beyond the aortic bifurcation: branched endovascular grafts for thoraco-abdominal and aortoiliac aneurysms. *J Vasc Surg* 2006;43:879-886.
11. Casey K, Al Khatib WK, Zhou W. Hypogastric Artery Preservation During Aortoiliac Aneurysm Repair. *Ann Vasc Surg* 2011;25:133 e1-8.
12. Donas KP, Torsello G, Pitoulis GA, Austermann M, Papadimitriou DK. Surgical Versus Endovascular Repair by Iliac Branch Device of Aneurysms Involving the Iliac Bifurcation. *J Vasc Surg* 2011; 53: 1223-1229.
13. Lobato AC, Camacho Lobato L. The sandwich technique to treat complex aortoiliac or isolated iliac aneurysms: Results of midterm follow up. *J Vasc Surgery* 2013;57(2)Supplement:26S-34S.
14. Arko FR, Lee WA, Hill BB, Fogarty TJ, Zarins CK. Hypogastric artery bypass to preserve pelvic circulation: improved outcome after endovascular abdominal aortic aneurysm repair. *J Vasc Surg* 2004; 39:404-408.
15. De Rubertis BG, Quinones Baldrich WJ, Greenberg JJ, Jimenez JC, Lee JT. Results of a Double Barrel Technique with Commercially Available Devices for Hypogastric Preservation During Aortoiliac Endovascular Abdominal Aortic Aneurysm Repair. *J Vasc Surg* 2012;56:1252-1259.
16. Verzini F, Parlani G, Romano L, et al. Endovascular treatment of iliac aneurysm: concurrent comparison of Side branch endograft versus hypogastric exclusion. *J Vasc Surg* 2009;49:1154-1161.
17. Ghosh J, Murray D, Paravastu S, Farquharson F, Walker MG, Serracino Ingloft F. Contemporary management of aortoiliac aneurysms in endovascular era. *Eur J Vasc Endovasc Surg* 2009;37:182-188.
18. Kritpracha B, Pigott JP, Price CI, Russell TE, Corbey MJ, Beebe HB. Distal Internal Iliac Artery Embolization: A Procedure to Avoid. *J Vasc Surg* 2003;37:943-948.
19. Vandy F, Criado E, Upchurch GR Jr, Williams DM, Rectenwald J, Eliaison J. Transluminal hypogastric artery occlusion with an Amplatzer vascular plug during endovascular aortic aneurysm repair. *J Vasc Surg* 2008;48:1121-1124.
20. Mehta M, Veith FJ, Darling RC, et al. Effects of bilateral hypogastric artery interruption during endovascular and open aortoiliac aneurysm repair. *J Vasc Surg* 2004;40:698-702.

Received: 11/07/2016

Accepted: 28/08/2016

Published: 15/09/2016

Disclosure and conflicts of interest:

The authors declare no conflict of interest.

Corresponding author:

Rocco Giudice

Mail: rgiudice@hsangiovanni.roma.it

Aortic surgery cost and outcome at teaching vs. non-teaching hospitals

Azam Jan¹, Naseer Ahmed², Mumtaz Anwar Shah¹, Somiya Rehman¹,
Alessio Rungatscher², Giuseppe Faggian²

¹) Department of Cardiac Surgery, Rehman Medical Institute, Peshawar, Pakistan.

²) Cardiac Surgery Division, University of Verona Medical School, Verona, Italy.

Abstract

Objective: The purpose of this was to investigate, if there is a difference in cost and outcomes of Aortic surgery in teaching hospitals as compared to non-teaching hospitals.

Methods: The Healthcare Cost and Utilization Project (HCUP), sponsored by The Agency for Healthcare Research and Quality's (AHRQ), includes the largest collection of longitudinal hospital care data in the United States of America. HCUP creates the National Inpatient Sample (NIS) to help conduct national and regional analyses of inpatient care. Using the NIS (2001-2012), we performed a retrospective cohort study that involved patients who underwent vascular. Bypass surgery involving major abdominal vessels. To identify these patients we used ICD (International Classification of Diseases) 9 procedure code 39.25. Using statistical analysis we compared the inpatient short term outcomes of these patients treated at teaching hospitals to non-teaching hospitals. Unweighted, it contains data from more than 7 million hospitalized patients stay each year. Weighted, it estimates more than 36 million hospitalizations nationally taken from more than 4,000 HCUP participating hospitals.

Results: A total of 15274 patients were analyzed from 2011-2012. There has been a marked decline in rate of Aortic bypass procedures per 100,000 discharges from 6.3 to 2.8 over the years 2001 to 2012. Also in these cases Routine discharges have decreased, the cost of stay and utilization of nursing home, rehabilitation and home health care has increased since 2001. There is no significant difference in inpatient mortality between teaching (3.06%) and non-teaching hosp. (4.21%). At teaching hospitals the cost of the admission for these aortic procedures was 6000\$ higher, the length of stay was longer. Overall the use of nursing home, rehabilitation and home health care is more by the academic hospitals. But there is no difference in utilization of these facilities when it is analyzed relative to total number of procedures, between teaching and non-teaching hospitals.

Conclusions: Teaching hospitals has similar mortality for aortic bypass procedures as compared to nonteaching hospitals but at a higher cost of re-admission and prolonged hospitalization.

Keywords: Vascular surgery, nursing home and rehabilitation, surgical mortality and morbidity.

Jan A. Ahmed N, Shah SM., Rehman S, Rungatscher A, Faggian G. Aortic surgery cost and outcome at teaching vs. nonteaching hospitals. *EJCM* 2016; 04 (3): 56-62. Doi: 10.15511/ejcm.16.00356.

Introduction

The university hospitals usually under pressure to face challenges for more complicated cases, patient care and research activities.^[1-5] The Committee on Quality of Health Care in America, of the “Institute of Medicine” concluded that it is not acceptable for patients to be harmed by the health care system that is supposed to offer healing and comfort-- a system that promises, ‘First, do no harm’^[6] Similarly it is our duty to maintain high standards of medical training for the doctors and other medical professionals of the future, at hospitals, without compromising any patient safety issues. Tremendous effort has been put in to implement and assess these two fundamental goals of academic medical institutions. There are different studies looking at the impact of trainees involved in surgical cases, showing difference in operating time and transfusion requirements etc.^[7] We wanted to see how adding teaching to health care institutions would actually impact treatment of surgery patients. To investigate that we decided to look at the multiyear data provided by The Agency for Healthcare Research and Quality’s (AHRQ).^[8]

Materials and Methods

AHRQ’s mission is to produce evidence to make health care safer, higher quality, more accessible, equitable, and affordable. The Healthcare Cost and Utilization Project (HCUP) is a family of databases and related software tools and products developed through a Federal-State-Industry partnership and sponsored by AHRQ. HCUP includes the largest collection of longitudinal hospital care data in the United States. The data in the HCUP databases primarily include data from non-federal community hospitals. HCUP creates the National Inpatient Sample (NIS) to make it possible for researchers to conduct national and regional analyses of hospital use and the hospital charges and costs associated with inpatient care. The NIS is derived from the State Inpatient Databases (SID) and approximates a 20% sample of discharges from all HCUP community hospitals in the U.S. The NIS is the largest publicly available all-payer inpatient health care database in the United States, yielding national estimates of hospital inpatient stays. Unweighted, it contains data from more than 7 million hos-

pital stays each year. Weighted, it estimates more than 36 million hospitalizations nationally taken from more than 4,000 HCUP participating hospitals.

We wanted to primarily assess the impact of the academic status of the institutions on patient outcome of surgery patients. Hence we picked up a group of surgeries performed at hospitals, which would have required multidisciplinary perioperative and intraoperative management. With this in mind, using the National Inpatient Sample database, we performed a retrospective cohort study that involved patients who underwent vascular Bypass surgery involving major abdominal vessels. The Institutional Review Board approval was waived. To identify these patients we used ICD 9 CM procedure code 39.25.^[9] This code includes the following procedures aorto-femoral, aorto-iliac, aorto-iliac to popliteal, aorto-popliteal and ilio-femoral bypass. Then using national estimates, we identified associations of patient demographics, and hospital characteristics with inpatient postoperative outcomes. We queried our desired ICD 9 code using HCUP net, which is a free, on-line query system based on NIS data.

The definition of all the patients, hospital demographics and outcome measures are available on HCUP net. We first analyzed the national trends of this ICD code from year 2001 to 2012. Then we restricted the discharges to Operating room procedures only, which are defined as “valid O.R. procedures” based on Diagnosis Related Groups coding principles. Then we did a detailed analysis of 2012 data, so that we can have outcomes representing the most recent advances in medical care provided in the latest academic environment. Using this data we did stratification based on the teaching status of the institution.

According to NIS a hospital is considered a teaching hospital if it meets any one of the following three criteria: Residency training approval by the Accreditation Council for Graduate Medical Education (ACGME), Membership in the Council of Teaching Hospitals (COTH) or A ratio of full-time equivalent interns and residents to beds of 25 or higher. We analyzed 2012 variables “Urban nonteaching” and “Urban teaching” and their effect on mortality and discharge status. In addition we also investigated

effect of hospital volume and geographical location on inpatient outcomes.

We used Excel and HCUP Z score calculator for our statistical analysis. We considered a p value of less than 0.05 for significance. For continuous data we analyzed the actual numbers and for dichotomous data we used percentage comparisons to get a more meaningful result.

Results

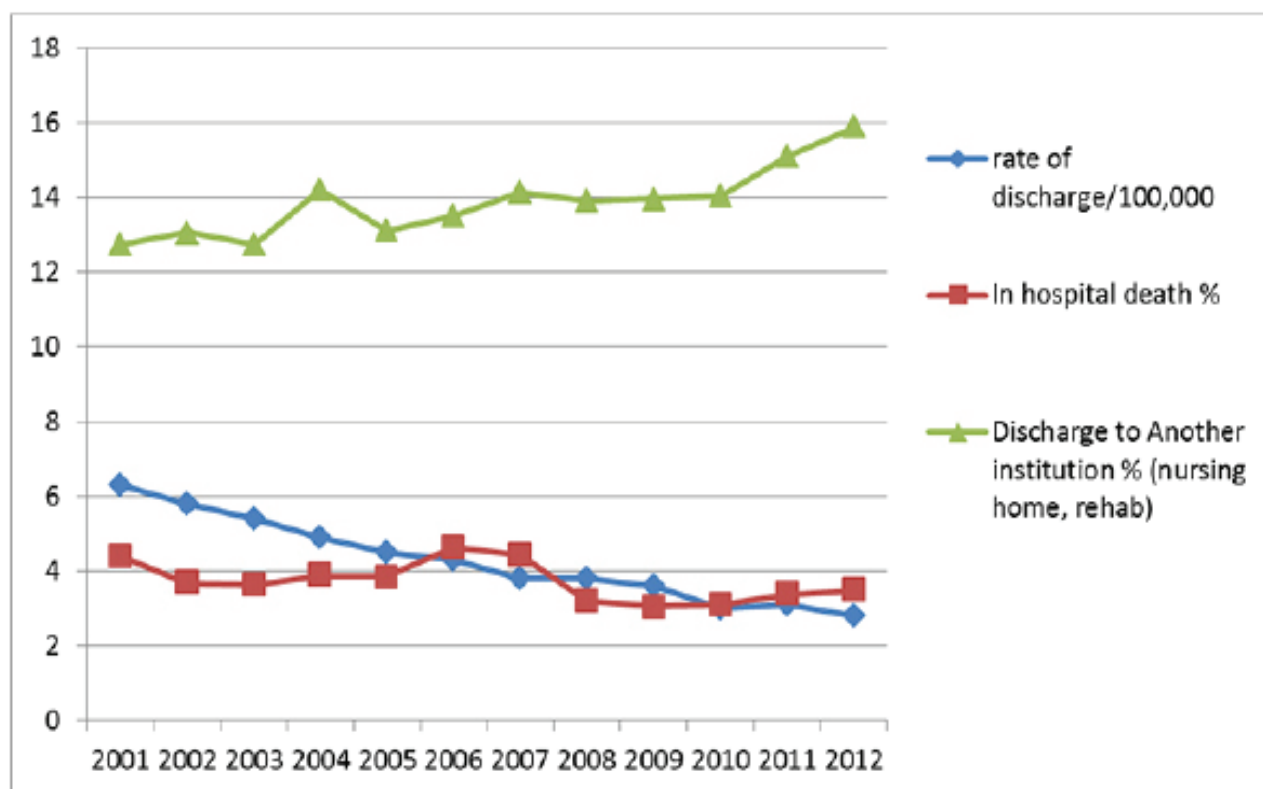
NIS database in the United States, unweighted, contains data from more than 7 million hospital stays each year. Weighted, it estimates more than 36 million hospitalizations nationally taken from more than 4,000 hospitals. A total of 152,474 patients were discharged with a primary ICD procedure code of major abdominal vascular procedures (39.25) from 2001 to 2012. There was a decline (significant p value <0.05) in total discharges (from 18065 to 8755) and rate of discharge per 100,000 persons (6.3 to 2.8) from 2001 to 2012. (Figure 1). The Length of stay remained constant around 8 days during this time period.

The total charges of these procedures (ICD code 39.25) has increased significantly to more than 100,000\$ in 2012 which was more than double of what it was in 2001. Also there is a significant decrease of 10% in routine discharges but no difference in discharge to another short term hospital since 2001. There is a 3 % increase in use of nursing home, rehabilitation institutions and 8% increase in home health care since 2001. There is a statistically significant decrease in number of deaths from 2001 to 2012 i.e. 794 to 305 respectively but the percentage decrease in mortality from 4.39% to 3.48% (p value 0.09) has a decreasing trend but (at p value of 0.05) is not significant.

Total of 8755 patients were discharged with this ICD code in 2012. In 2012 60% patients were males, Medicare was the payer of 50% patients and 30% patients had insurance. 78% admissions were at private-not for profit institutions, 60 % were at teaching hospitals and 47% patients were from south region.

In total 5230(60%) were from urban teaching hospi-

Figure 1. 2001-2012 National statistics (ICD code) 39.25 for Aortic Bypass. Weighted national estimates from HCUP National Inpatient Sample (NIS).



tals and 2970(34%)were from non-teaching hospitals. 6% patients were from rural hospitals ,so their data were not included in further analysis of 2012 data.

There were significantly more discharges from urban teaching hospitals (**Table 1**). Discharges from teaching hospitals had statistically significant differences as compared to nonteaching hospitals, including a longer length of stay, more cost of treatment, less routine discharges, more discharges to nursing home and rehab and more utilization of home health care when total numbers were analyzed. When we did comparison based on percentage differences there was no statistical difference between routine discharges, discharges to nursing home and rehab and utilization of home health care. Although there was a lower Inpatient mortality, by 1%, at teaching hospitals, this difference was not statistically significant.

We analyzed risk factors for higher mortality (**Table 2**). Risk factor for higher mortality was age of 65 to 84 and factors that did not have statistically different im-

pact on mortality included sex of the patient, teaching status of the hospital, geographical location, and median income for the zip code, ownership type and size of the hospital.

Discussion

We had a large number of patient population and very reliable data source to analyze. But these databases are derived from billing data and some useful data, such as pharmacy and laboratory information, are not included. Also, as with any administrative healthcare database, there may be issues with coding accuracy. But still with a large number of patients, very useful assumptions can be made. There are different aortic procedures included in our research design, which in turn vary in complexity and periprocedural risk of death and complications. The decrease in overall rate of these procedures over the years probably corresponds to the increase in endovascular procedures. That probably also has an impact on increase in the complexity of these procedures. As more complicated procedures are being performed as

Table 1. Academic status of the hospital and Inpatient Postop. outcomes of vascular surgery patients(ICD 9 39.25 Aorta-Iliac-Femoral Bypass)

2012 year	Non-teaching Hosp.	Urban Teaching Hosp.	P value (two tail)
Total number of discharges	2970	5230	0.00 (significant)
LOS (length of stay), days (mean)	7.7	9.2	0.00 (significant)
Costs, \$ (mean)	25237	31579	0.00 (significant)
In-hospital deaths	125 (4%)	160 (3%)	0.23 (non sign % diff.)
Routine Discharge	1855 (62%)	3060(59%)	0.15 (nonsign % diff)
Discharge to Another institution (nursing home, rehab)	435 (15%)	895 (17%)	0.20 (nonsign % diff)
Home health care	510 (17%)	1050(20%)	0.20 (nonsign % diff)

Weighted national estimates from HCUP National Inpatient Sample (NIS), 2012. Significant at $p < .05$

Table 2. 2012 National statistics (ICD code) 39.25 Aorta-Iliac-Femor Bypass Mortality

All discharges		Total number of discharges	In-hospital deaths	Z test between % of in hospital deaths
		8,755 (100.00%)	305 (3.48%)	P value (two tail)
Age group	<1	*	*	0.00 (significant) Between 45-64 and 65-84
	1-17	*	*	
	18-44	265 (3.03%)	*	
	45-64	4,935 (56.37%)	85 (1.72%)	
	65-84	3,425 (39.12%)	200 (5.84%)	
	85+	120 (1.37%)	*	
Sex	Male	5,230 (59.74%)	185 (3.54%)	0.09 (Non sig) Male and female
	Female	3,525 (40.26%)	120 (3.40%)	
Payer	Medicare	4,370 (49.91%)	220 (5.03%)	
	Medicaid	1,035 (11.82%)	*	
	Private insurance	2,540 (29.01%)	*	
	Uninsured	480 (5.48%)	*	
	Other	275 (3.14%)	*	
	Missing	*	*	
Median income for Zip code	Low	2,905 (33.18%)	95 (3.27%)	0.64 (non significant) Low vs. Not Low
	Not low	5,695 (65.05%)	210 (3.69%)	
Owner	Government	840 (9.59%)	*	0.09 (non significant) Private Not for profit vs. private for profit
	Private, not-for-profit	6,795 (77.61%)	210 (3.09%)	
	Private, for-profit	1,120 (12.79%)	65 (5.80%)	
Location / teaching status	Rural	555 (6.34%)	*	0.23 (non significant) Nonteaching vs. teaching
	Urban nonteaching	2,970 (33.92%)	125 (4.21%)	
	Urban teaching	5,230 (59.74%)	160 (3.06%)	
Bedsizes	Small	860 (9.82%)	*	0.21 (non significant) Medium vs. Large
	Medium	1,820 (20.79%)	80 (4.40%)	
	Large	6,075 (69.39%)	180 (2.96%)	
Region	Northeast	1,275 (14.56%)	*	0.377 (non significant) Midwest vs. south
	Midwest	2,445 (27.93%)	100 (4.09%)	
	South	4,135 (47.23%)	130 (3.14%)	
	West	900 (10.28%)		

Weighted national estimates from HCUP National Inpatient Sample (NIS), 2012. Statistics based on estimates with a relative standard error (standard error / weighted estimate) greater than 0.30 or with standard error = 0 are not reliable. These statistics are suppressed and are designated with an asterisk (*). Significant at $p < .05$

open aortic bypasses, we expect more utilization of rehabilitation and nursing homes. That could be one of the reasons for that change over the decade studied.

Teaching hospitals have an increased cost and longer stay for surgical admissions. As any one vascular procedure can be performed for different reasons that reflect different levels of disease severity, which can influence unadjusted rates of events. For instance, the same aorto-femoral bypass can be performed for gangrene of the foot to prevent amputation, or alternatively for intermittent claudication or an aneurysmal condition. Comparison of outcomes among different vascular surgery practices must therefore account for potential differences in the range of procedures being performed. If teaching hospitals are undertaking more complicated procedures then some of the differences can be explained. From our study, we assumed that there is no significant difference between teaching and non-teaching hospitals mortality rate. And if that is the case then having a similar mortality hints towards providing better care. It could be that the trainees order more diagnostic

tests and assess discharge disposition differently than consultant physicians?

Limitations

We used national database, where we have limitations in some data and some parameters to assess investigations level. Having 30 day mortality data and more detail of patient demographics will help us throw more light on quality of care.

Conclusion

Teaching hospitals has similar mortality for aortic surgery procedures as compared to non-teaching hospitals but at a higher cost of admissions and prolonged hospitalization.

Acknowledgements: *The authors acknowledge all of the HCUP Data Partners that contribute to HCUP. List of these State organizations can be accessed at (www.hcup-us.ahrq.gov/hcupdatapartners.jsp).*

References

1. Iglehart JK. Rapid changes for academic medical centers. N Engl J Med 1994; 331: 1391–1395.
2. Epstein AM. US teaching hospitals in the evolving health care system. JAMA 1995; 273: 1203–1207.
3. Iglehart JK. Rapid changes for academic medical centers, II. N Engl J Med 1994; 332: 407–411.
4. Kassirer JP. Academic medical centers under siege. N Engl J Med 1994; 331: 1370–1371.
5. Whitcomb ME, Cleverly WO. Financial performance of academic medical center hospitals. Acad Med 1993; 68: 729–731
6. Linda T. Kohn, Janet M. Corrigan, and Molla S. Donaldson. November 1999 Shaping the Future for Health TO ERR IS HUMAN: BUILDING A SAFER HEALTH SYSTEM. Committee on Quality of Health Care in America, INSTITUTE OF MEDICINE.NATIONAL ACADEMY PRESS. Washington, D.C.
7. Azam Jan, MD, Dale R. Riggs, BA, Keri L. Orlando, RN†, Fawad J. Khan, MD.Surgical Outcomes Based on Resident Involvement: What Is the Impact on Vascular Surgery Patients? Journal of Surgical Edu. Volume 69, Issue 5, September–October 2012, Pages 638–642
8. The Agency for Healthcare Research and Quality's (AHRQ), The Healthcare Cost and Utilization Project (HCUP), State Inpatient Databases (SID) and National Inpatient Sample (NIS) . <http://www.ahrq.gov>
9. The Centers for Medicare & Medicaid Services ICD 9 CM : International Classification of Diseases, Clinical Modification .

Received: 17/07/2016

Accepted: 02/09/2016

Published: 15/09/2016

Disclosure and conflicts of interest:

Article have been presented at 12th Update congress of Cardiology and Cardiac Surgery, (10th March-13th March 2016) Antalya, Turkey.

Corresponding author:

Naseer Ahmed

Mail: dr.naseer99@gmail.com

Jan A. Ahmed N, Shah SM., Rehman S, Rungatscher A, Faggian G. Aortic surgery cost and outcome at teaching vs. nonteaching hospitals. EJCM 2016; 04 (3): 56-62. Doi: 10.15511/ejcm.16.00356.

The minimally invasive right vertical infra-axillary lateral minithoracotomy approach for the heart valve surgery: Report of 115 cases

Mahmut Akyıldız¹, Ahmet Refik Turgut¹, Taner Şerif Küçükcerit², Güzin Kaşo²,
Remzi Tosun¹, Noyan Temuçin Oğuş¹

¹) Department of Cardiovascular Surgery, Medistate Kavacık Hospital, Istanbul, Türkiye

²) Department of Anesthesiology, Medistate Kavacık Hospital, Istanbul, Türkiye

Abstract

Objective: We have developed a minimally invasive technique for heart valve replacements through a lateral minithoracotomy via a small right infra-axillary skin incision, and have evaluated its initial results.

Methods: Through right vertical infra-axillary lateral minithoracotomy incision (by third intercostal space), 106 patients with rheumatic heart valve disease underwent heart valve surgery, 4 patients with left atrial myxoma and 5 patient with large atrial septal defect underwent open heart operation are included in this study from July 2012 to December 2015.

Results: 42 isolated mitral valve replacements, 7 mitral valve replacements and DeVega tricuspid annuloplasty, 3 mitral and tricuspid valve replacement, 2 mitral valve replacement and right coronary artery bypass graft, 1 reoperative mitral valve replacement due to degeneration of the bioprosthesis of the mitral valve, 6 mitral valve repair, 1 mitral valve repair and aortic valve replacement; 33 isolated aortic valve replacements, 9 aortic and mitral double valve replacements, 2 triple valve replacements, 4 excision of the left atrial myxoma and 5 surgical closure of the large atrial septal defect were performed. There were 52 women (45%) and 63 men (55%). The mean and range of age was 48±9 (14-91). The length of the incision averaged 8.5±0.5 cm, There were 4 operative mortalities, one patient from infective endocarditis and multisystem organ failure, the other patients from cardiac failure in the hospital. The results of follow up for other patients were fine.

Conclusions: This minimally invasive right vertical infra-axillary lateral minithoracotomy approach is safely, practicable, useful, economic, small wounded, cosmetic, contemporary and modern approach for the heart valve surgery

Keywords: infra-axillary, minithoracotomy, minimally-invasive cardiac surgery

Akyıldız M., Turgut A. R., Küçükcerit T. Ş., et al. The minimally invasive right vertical infra-axillary lateral minithoracotomy approach for the heart valve surgery: report of 115 cases EJCM 2016; 04 (3): 63-70. Doi: 10.15511/ejcm.16.00363.

Introduction

The operation for valve replacement and repair over the past 40 years has evolved to using a median sternotomy incision, cardiopulmonary bypass, varying degrees of systemic hypothermia, antegrade and retrograde cardioplegic myocardial protection. With the establishment of the minimally invasive major surgery in orthopedic, gynecologic, urologic, general surgery and thoracic surgery over the past 25 years, cardiac surgeons over the past 15 years have begun to explore the use of minimally invasive approaches for patients undergoing standard cardiac valve operations. Minimally invasive valve surgery was first performed by Navia et al. in 1996, and by Cohn et al. in 1997.^(1,2)

Material and Methods

From July 2012 to December 2015, 115 operations using a minimally invasive approach through the right vertical infra-axillary lateral minithoracotomy incision (by intercostal space) were performed in our clinic. 106 patients with rheumatic heart disease underwent heart valve replacement and 4 patients with left atrial myxoma and 5 patients with large atrial septal defect underwent open heart operation are included in this study. All patients were entered into our clinic's cardiac surgery database to prospectively document preoperative indications, in-hospital and post-hospital operative morbidity and mortality, patient satisfaction was analyzed which included reliance on pain medicine and return to full activity.

Operative Techniques

Setting of the patient is left lateral decubitus and slightly posterior oblique position (10°-20° posterior oblique, left decubitus, right lateral thoracotomy position) with a support under patient's back. The patients undergoing heart valve replacement were treated by using a minimally invasive approach through the right vertical infra-axillary lateral minithoracotomy incision usually by third intercostal space for our operation, sometimes by fourth intercostal space for some patients which have tall and bulky body, the incision is made approximately 6 to 10 cm in the right infra-axillary, oblique, lateral minithoracotomy. After the incision, pulmonary tidal volume is decreased about half of the tidal volume

and respiratory rate is increased to 16-18 breaths per minute. This manipulation is usually sufficient for exposure of the pericardium, therefore we don't need using double-lumen endotracheal Carlens tube for selective pulmonary ventilation. Then right pulmonary lobes can easily be retracted posteriorly using a pulmonary retractor and pericardium is opened 3-4 cm anterior to the phrenic nerve. The edges of the pericardium are attached to the skin by retraction stitches. This pericardial retraction raises the heart 4 to 5 cm to the operative field. The aorta, right and left atrium, superior and posterior vena cava are exposed. After heparinization, the femoral artery is cannulated with standard femoral artery cannula, superior and inferior vena cava are cannulated with curved venous canulas.

After cannulation, cardiopulmonary bypass is begun and systemic temperature is lowered to 28 °C. Caval tapes are put down. The aorta is cross-clamped with a specific flexible minimally invasive cross-clamp. Antegrade cold blood cardioplegia solution is delivered for cardiac arrest. The right atrium is opened and a retrograde cardioplegia cannula is inserted after placement of purse string sutures to the coronary sinus ostium, then antegrade and retrograde cold blood cardioplegia solution are administered for cardiac arrest and myocardial protection and then the cardiac valve replacement or repair is performed using the standard techniques. All valve repair operations are checked by intraoperative transesophageal echocardiography.

Results

Table 1 lists demographics for patients undergoing minimally invasive valve surgery, including age, gender, functional class and valve etiology. **Table 2** lists operative procedures of minimally invasive cardiac valve surgery. **Table 3** outlines operative mortality and postoperative morbidity. The postoperative mortality for minimally invasive cardiac valve surgery was 4 (3.47 %) of 115.

In the mitral valve group, 42 patients (36.52%) had isolated mitral valve replacement (MVR), 7 patients (6.08%) had MVR and De Vega Trikuspid Annuloplasty, 3 patients (2.61%) had mitral and trikuspid valve replacement, 2 patients (1.74%) had mitral valve replace-

ment and right coronary artery bypass graft, 1 patient (0.87%) had reoperative mitral valve replacement due to degeneration of the bioprosthesis of the mitral valve, 6 patients (5.22%) had mitral ring annuloplasty which included The St Jude Saddle ring annuloplasty, showed minimal to trace mitral regurgitation by intraoperative and postoperative transesophageal echocardiography and 1 patient (0.87%) had mitral ring annuloplasty and aortic valve replacement.

In the aortic valve group, 33 patients (28.69%) had isolated aortic valve replacement (AVR) and 9 patients

(7.83%) had aortic and mitral valve replacements and 2 patients (1.74%) had triple valve replacements.

For isolated mitral valve replacement (MVR), arrest times averaged (69.5 +/- 10) min, cardiopulmonary bypass times averaged (98.5 +/-10) min.

For isolated aortic valve replacement (AVR), arrest times averaged (79.2 +/- 15) min, cardiopulmonary bypass times averaged (110.7 +/-15) min.

For aortic and mitral valve replacement (AVR and MVR), arrest times averaged (141.6.5 +/- 20) min, car-

Table 1. Demographics for patients

Diagnosis	Patients	
MVR was operated, isole MR	17	
MVR was operated, MS and MR /	7.7	9.2
complex mitral valve disease	25	
Mitral and tricuspid valve disease	10	
Isole MR and Right coronary artery disease	2	
Mitral bioprotez restenozu	1	
MRA was operated, isole MR	6	
Isolated aortic valve insufficiency	9	
Complex aortic valve disease / AS and AI	24	
Aortic and mitral valve disease	9	
Three valves disease	2	44-38.26%
Myxsoma	4	
Large asd	5	9-7,82%
Total	115	115-100%

MVR: mitral valve replacement **MR:** mitral regurgitation **MS:** mitral valve stenosis **MRA:** mitral ring annuloplasty **AI:** aortic valve insufficiency **AS:** aortic valve stenosis

Table 2. Minimally invasive cardiac valve surgery

Operative Procedures of the Minimally Invasive Cardiac Surgery		
Mitral Valve Replacement (MVR)	42	(36,52 %)
MVR + DeVega Tricuspid Annuloplasty	7	(6.08 %)
MVR + Tricuspid Valve Replacement	3	(2.61 %)
MVR + CABGX1 (SV-RCA)	2	(1.74 %)
Redo MVR	1	(0.87 %)
Mitral Ring Annuloplasty	6	(5.22 %)
Mitral Ring Annuloplasty + AVR	1	(0.87 %)
Aortic Valve Replacement (AVR)	33	(28.69 %)
Aortic and Mitral Valve Replacement	9	(7.83 %)
-- previous CMC operation	1	
-- with enlargement of aortic annulus	1	
--double bioprosthesis valve	2	
Triple Valve Replacement	2	(1.74 %)
Myxsoma	4	(3.48 %)
Surgical closure of the large ASD	5	(4.35 %)
Total	115	(100 %)

MVR: mitral valve replacement **AVR:** aortic valve replacement **CABG:** coronary artery bypass grefting operation **SV:** saphenous vein **RCA:** right coronary artery **CMC:**Closed Mitral Commissurotomy

diopulmonary bypass times averaged (175.3 +/-20) min.

Ventilator periods averaged (7.5 +/- 2.5) hour, chest tube drainage averaged (350 +/- 150) ml. Two patients were reoperated on for bleeding. There were zero wound infections of the thoracic and groin incisions. The length of the incision averaged (8.5 +/- 0.5) cm.

In the medium-term follow-up extending to December 2015, there was four hospital death, one of these hospital mortalities was in class IV patients from endocarditis, the other all patients improved at least two functional classifications in The New York Heart.

Discussion

Cardiac valve replacement and repair for the adult patient has become an exceedingly effective operative therapy for congenital, rheumatismal, degenerative lesions of both the aortic and mitral valve. These operations over the past 40 years have been performed through the standard complete median sternotomy and cardiopulmonary bypass with intrathoracic cannulations. With the advent of minimally invasive cardiac valve surgery, several new observations have arisen regarding the treatment of patients with isolated valve

disease. Certainly, trauma is considerably less with the minimally invasive incisions. Sternal infections are avoided and there is less blood loss from the incision and the operative site.⁽²⁾

Minimally invasive valve surgery was first performed by Navia et al. in 1996, and by Cohn et al. in 1997.^(1,2) When compared with a standard median sternotomy approach, the reported benefits of minimally invasive valve surgery include: reduced blood loss and pain, a lower morbidity, an enhanced recovery with shorter intensive care unit and hospital length of stay.⁽²⁻⁸⁾ Overall, the studies performed have involved single valve surgery in lower risk patients.

Lamelas et al. have compared the outcomes of minimally invasive valve surgery with median sternotomy in high risk patients,⁽⁹⁾ Lamelas have demonstrated a reduced morbidity and lower resource utilization in those patients with chronic kidney disease,⁽¹⁰⁾ chronic obstructive pulmonary disease,⁽¹¹⁾ those requiring reoperative mitral valve⁽¹²⁾ and aortic valve⁽¹³⁾ surgery. In addition, they observed a reduction in mortality in the elderly⁽¹⁴⁾ and obese⁽¹⁵⁾ patients. Because of these benefits, especially in high risk patients, it is reasonable to hypothesize that those needing concomitant aortic and mitral valve surgery would also benefit from a minimally invasive approach.

In this our series of 96 patients, only 2 patients had to revision for the postoperative bleeding, whereas mean RBCs usage was 2.4 U in the our minimally invasive valve surgery group. There is improved cosmetic with these incisions which are relatively small, particularly for slim, underweight patients.

Techniques of minimally invasive surgery include for mitral valve, a port access system,⁽¹⁶⁾ which actually does mitral valve surgery through an even smaller transverse incision under the right breast fold and is more cosmetically; for aortic valve partial upper T or L shaped ministernotomy or right anterior minithoracotomy,⁽¹⁷⁾ for combined aortic and mitral valve surgery, a minimally invasive approach, performed via a right anterolateral thoracotomy (The "Miami Method");⁽⁹⁾ for double or triple valve performed via a right anterolateral thoracotomy by Karimov et al. in 2009⁽¹⁸⁾ and 2010⁽¹⁹⁾

Table 3. Minimally invasive valve surgery operative Morbidity and mortality

Due to pleural hemoragyc effusion, torasentesis	5
Pericardial effusion	(-)
Elevation of the right diaphragma	3
Groin complications	(-)
Intraoperative dissection	(-)
Reoperation on for bleeding	2
Mean RBCs used	2.4
Postoperative IABP required	5
Postoperative ECMO required	2
Endocarditis	1
Mortality	4

For single, double, even triple valve replacement operations, surgical closure of the large ASD, myxoma excision, concomitant AF ablation and concomitant right coronary artery bypass grafting operations, performed via a right vertical infra-axillary lateral minithoracotomy by our surgical team. This minimally invasive techniques for mitral or aortic valve performed by Wang et al. in 1999,⁽²⁰⁾ for mitral valve performed by Tüneriret al. in 1999⁽²¹⁾ and Beşoğlu et al. in 2002,⁽²²⁾ for aortic valve performed by Ito et al. in 2015.⁽²³⁾

In 1996, Carpentier performed the first video-assisted minimally invasive mitral valve surgery (MIMVS) through a mini-thoracotomy⁽²⁴⁾ and Chitwood introduced the transthoracic aortic clamp.⁽²⁵⁾ In 1998, Mohr developed a video-assisting port access technology to reduce CPB and cross-clamp times which allowed a better visualization of the valve.⁽²⁶⁾

Since then, MIMVS has been performed through a wide variety of approaches (hemisternotomy, parasternal incision, mini-thoracotomy, total endoscopically and robotically) with favourable long-term outcomes even in elderly and redo patients when compared with sternotomy despite longer bypass and cross-clamp times.⁽²⁷⁻²⁸⁾ However, minimally invasive cardiac surgery is always accompanied by a learning curve.

The pain in these incisions is considerably less than in the patients with the median sternotomy, especially late period after the surgery. There is significantly less

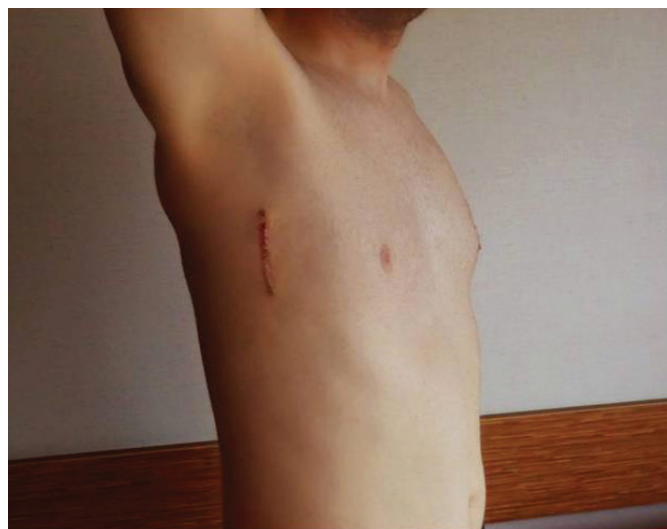incisional pain, less requirement for pain medication both in the hospital and early period after the surgery, and a faster return to normal usual activity.⁽²⁻⁸⁾

In this our series, postoperative first day, all of the patients could abduct their right arm about 90 degrees.

A disadvantage has been use of the femoral artery for cannulation, retrograde dissection may occur, and groin complications such as groin infections, arteries requiring reconstruction can be seen and were, in fact, a source of minor morbidity to the patient.^(20,21,22) In our series, we don't have any complication about retrograde dissection and groin complications.

The major question to be asked is this: can you achieve the same quality of operation that you can do through the complete median sternotomy without complete exposure of the heart? The answer, based on our experience and the other authors which are minimally invasive surgeons, is an emphatic "yes". The quality of the valve replacement and repair in both the aortic and mitral has been exactly equal to the standart operation. There have been no perivalvular leaks in any of the valves implated, and there has been excellent visualization of the valves as to perform valve implantation or repair, and documented by intraoperative and postoperative by transesophageal echocardiography. Thus, we believe that the quality of the valve operations has not been mitigated in any way. Conversely, we have learned that in the extremely older and sick patients with a high degree of the risk and potential morbidity, these minimally invasive prosedures may not be as useful.

Finally, minimally invasive aortic and mitral valve surgery in patients without coronary disease can be done safely and accurately through small incisions. Patient satisfaction is up, return to normality is higher, and requirement for post-hospital care is less. If the same quality of the operation can be performed through a less traumatic and better cosmetic incision resulting in less hospital stay and a lower overall cost, if the operation can be performed as effectively as the operation with the standard complete median sternotomy and significantly reduce the need for post-operative care, the minimally invasive valve surgery can be preferred.



Conclusion

Minimally invasive right vertical infra-axillary thoracotomy has two main advantages: Cosmetic appearance and patient comfort. Cosmetic appearance is very important for younger patients. The incision is so placed that the patient can not see the incision site without using a mirror. So, many patients, especially younger patients, prefer this technique to a median sternotomy and to other minimally invasive thoracotomy incisions. Nearly half of our patients were younger than 40 years. Compared to other minimally invasive techniques, we believe that the right vertical infra-axillary lateral approach is cosmetically more acceptable for patients.

Postoperative patient comfort, the patient can perform almost all activities without difficulty or discomfort, such as lying in bed in any position, arising from

bed without help, using upper extremities without limitation, and early return to daily activities. Hence, higher patient satisfaction. Elderly patients have an increased risk for dehiscence of the standard sternotomy site. Overweight patients may have sleep apnea and thus can not lie in the supine position. These risks can be avoided by using this technique.

Surgical advantages: Less postoperative pain, no sternal infections, less blood loss, faster recovery, shorter intensive care unit and hospital stay, lower overall costs, lower morbidity and mortality. The quality of valve operations is not at all less with this technique.

Last, but not least, this technique presents particular difficulties for the surgeon. It is demanding, and have a learning curve. Only a dedicated team can have a successful result.

References

- Navia JL, Cosgrove DM. Minimally invasive mitral valve operations. *Ann Thorac Surg* 1996;62:1542-4.
- Cohn LH, Adams DH, Couper GS, et al. Minimally invasive cardiac valve surgery improves patient satisfaction while reducing costs of cardiac valve replacement and repair. *Ann Surg* 1997;226:421-6.
- Mihaljevic T, Cohn LH, Unic D, et al. One thousand minimally invasive valve operations: early and late results. *Ann Surg* 2004;240:529-34.
- Doll N, Borger MA, Hain J, et al. Minimal access aortic valve replacement: effects on morbidity and resource utilization. *Ann Thorac Surg* 2002;74:S1318-22.
- Raja SG, Navaratnarajah M. Impact of minimal access valve surgery on clinical outcomes: current best available evidence. *J Card Surg* 2009;24:73-9.
- Brown ML, McKellar SH, Sundt TM, et al. Ministernotomy versus conventional sternotomy for aortic valve replacement: a systematic review and meta-analysis. *J Thorac Cardiovasc Surg* 2009;137:670-679.e5.
- Murtuza B, Pepper JR, Stanbridge RD, et al. Minimal access aortic valve replacement: is it worth it? *Ann Thorac Surg* 2008;85:1121-31.
- Modi P, Hassan A, Chitwood WR Jr. Minimally invasive mitral valve surgery: a systematic review and meta-analysis. *Eur J Cardiothorac Surg* 2008;34:943-52.
- Lamelas JI. Minimally invasive aortic valve replacement: the "Miami Method". *Ann Cardiothorac Surg*. 2015 Jan;4(1):71-7.
- Valdez GD, Mihos CG, Santana O, et al. Incidence of post-operative acute kidney injury in patients with chronic kidney disease undergoing minimally invasive valve surgery. *J Thorac Cardiovasc Surg* 2013;146:1488-93.
- Santana O, Reyna J, Benjo AM, et al. Outcomes of minimally invasive valve surgery in patients with chronic obstructive pulmonary disease. *Eur J Cardiothorac Surg* 2012;42:648-52.
- Mihos CG, Santana O, Lamas GA, et al. Outcomes of right mini-thoracotomy mitral valve surgery in patients with previous sternotomy. *Ann Thorac Surg* 2011;91:1824-7.
- Pineda AM, Santana O, Reyna J, et al. Outcomes of aortic valve replacement via right mini-thoracotomy versus median sternotomy in patients with previous cardiac surgery. *J Heart Valve Dis* 2013;22:50-5.
- Lamelas J, Sarria A, Santana O, et al. Outcomes of minimally invasive valve surgery versus median sternotomy in patients 75 years or greater. *Ann Thorac Surg* 2011;91:79-84.
- Santana O, Reyna J, Grana R, et al. Outcomes of minimally invasive valve surgery versus standard sternotomy in obese patients undergoing isolated valve surgery. *Ann Thorac Surg* 2011;91:406-10.
- Minimally invasive mitral valve surgery--clinical experiences with a PortAccess system. Guliemos V, Wunderlich J, Dangel M, Wagner FM, Karbalai P, Reichensperner H, Tugtekin SM, Schueler S. *Eur J Cardiothorac Surg*. 1998 Oct; 14 Suppl 1:S148-53.
- Phan K, Xie A, Tsai YC, Black D, Di Eusano M, Yan TD. Ministernotomy or minithoracotomy for minimally invasive aortic valve replacement: a Bayesian network meta-analysis. *Ann Cardiothorac Surg* 2015;4(1):3-14.
- Karimov JH, Bevilacqua S, Solinas M, Glauber M. Triple heart valve surgery through a right anterolateral minithoracotomy. *Interact Cardio-Vasc Thorac Surg* 2009; 9: 360-362.
- Karimov JH, Solinas M, Latsuzbaia K, Murzi M, Cerillo AG, Glauber M. Surgical treatment of double and triple heart valve disease through a limited single-access right minithoracotomy. *Oxford Journals, Medicine & Health, Multimedia Manual Cardio-Thoracic Surgery, Volume 2010, Issue 0122, 10.1510/mmcts.2009.004036*
- Wang D, Wu Q, Yang X, Hua Z. Minimally invasive approach for heart valve replacement: report of 73 cases, *Zhonghua Wai Ke Za Zhi*. 1999 Apr;37(4):243-4.
- Tünerir B, Beşoğlu Y, Yavuz T ve ark. Mitral kapak replasmanında mediyen sternotomiye alternatif bir yöntem: sağ minitorakotomi. *GKDC Dergisi* 1999;8: 100-5.
- Yavuz Beşoğlu, Vefa Özcan, Turhan Yavuz, Bülent Tünerir, Recep Aslan. Açık Kalp Cerrahisinde Minimal İnvazif Sağ Anterolateral

- Minitorakotomi Deneyimlerimiz. Anadolu Kardiyol Derg, 2002; 4: 309-12
23. Ito T, Maekawa A, Hoshino S, Hayashi Y. Right infra-axillary mini-thoracotomy for aortic valve replacement. Ann Cardiothorac Surg 2015;4(1):57-58
24. Carpentier A, Loulmet D, Le Bret E, Haugades B, Dassier P, et al.[Open heart operation under videosurgery and minithoracotomy. First case (mitral valvuloplasty) operated with success]. C R Acad Sci III 1996;319:219-23.
25. Chitwood WR, Elbeery JR, Chapman WH, Moran JM, Lust RL, Wooden WA, et al Video-assisted minimally invasive mitral valve surgery: the ‘micromitral’ operation. J Thorac Cardiovasc Surg 1997;113:413-4.
26. Mohr FW, Falk V, Diegeler A, Walther T, van Son JA, Autschbach R. Minimally invasive port access mitral valve surgery. J Thorac Cardiovasc Surg 1998;115:567-76.
27. Goldstone AB, Atluri P, Szeto WY, Trubelja A, Howard JL, MacArthur JW Jr., et al. Minimally invasive approach provides at least equivalent results for surgical correction of mitral regurgitation: a propensity-matched comparison. J Thorac Cardiovasc Surg 2013;145:748-56.
28. Davierwala PM, Seeburger J, Pfannmueller B, Garbade J, Misfeld M, Borger MA, et al. Minimally invasive mitral valve surgery: the Leipzig experience. Ann Cardiothorac Surg 2013;2:744-50.

Received: 21/07/2016

Accepted: 18/08/2016

Published: 15/09/2016

Disclosure and conflicts of interest:

Conflicts of interest were not reported.

Corresponding author:

Dr. Ahmet Refik Turgut

Mail: ahmetrt@hotmail.com

Akyıldız M., Turgut A. R., Küçükcerit T. Ş., et al. The minimally invasive right vertical infra-axillary lateral minithoracotomy approach for the heart valve surgery: report of 115 cases EJCM 2016; 04 (3): 63-70. Doi: 10.15511/ejcm.16.00363.

Aortic aneurysm and mitral regurgitation as first manifestations of ankylosing spondilitis

Ertan Demirdaş¹, Kivanç Atılğan¹, Utkan Sevuk¹, Oğuz Taşdemir²

¹⁾ Bozok University Research and Application Hospital and Cardiovascular Surgery / Yozgat / Turkey

²⁾ Medicana International Hospital, Cardiovascular Surgery, Prof. Dr., Ankara, Turkey

Abstract

Ankylosing Spondilitis is a systemic inflammatory disease that involves the whole spine and sacroiliac joints. Cardiac manifestations include mitral regurgitation, aortic regurgitation, conduction abnormalities, atrial fibrillation, myocardial dysfunction and pericarditis. A 72 year-old male referring to our department because of dyspnea and mediastinal widening at chest radiography and having a diagnosis of aortic aneurysm and mitral regurgitation is presented as a case report.

Keywords: Ankylosing spondilitis, mitral regurgitation, aortic aneurysm, complication

A 72 year-old male was referred to our department because of dyspnea and mediastinal widening at chest radiography. Computed tomography (CT) scan of the chest with contrast revealed a 70x65mm saccular aneurysm of the arcus aorta with intraluminal thrombus and ascending aorta dilatation with a diameter of 45mm (**Figure 1**). Echocardiography revealed normal left ven-

tricular systolic function and severe mitral regurgitation. The patient has been suffering from low back pain for 10 years which have been considered to be associated with age-related degenerative changes and overlooked by the patient and the physicians. Preoperative Rheumatology consultation was requested to exclude vasculitis and the work-up revealed ankylosing spon-

Demirdaş E, Atılğan K., Sevuk U., Çiçekcioğlu F. Aortic aneurysm and mitral regurgitation as first manifestations of ankylosing spondilitis
EJCM 2016; 04 (3): 71-72. Doi: 10.15511/ejcm.16.00371.

dylitis (AS). Patient underwent an uneventful surgery. The aneurysm was repaired by Dacron patch-plasty. Leaflets of the mitral valve was severely thickened and was not suitable for repair. Thus, mitral valve was replaced using a mechanical valve. CT scan obtained 1 year after the operation demonstrated no abnormal findings at the repair site after patch angioplasty (**Figure 2**).

AS is a systemic inflammatory disease that involves the whole spine and sacroiliac joints. Cardiac mani-

festations include mitral regurgitation, aortic regurgitation, conduction abnormalities, atrial fibrillation, myocardial dysfunction and pericarditis.^[1,2] It should be kept in mind that, although extremely rare, aortic aneurysms and cardiac diseases may be the first manifestation of the AS and aortic aneurysms secondary to inflammatory diseases including AS are associated with an increased risk of relapse.^[1,3] Thus, patients should be followed up closely in the post-operative period.

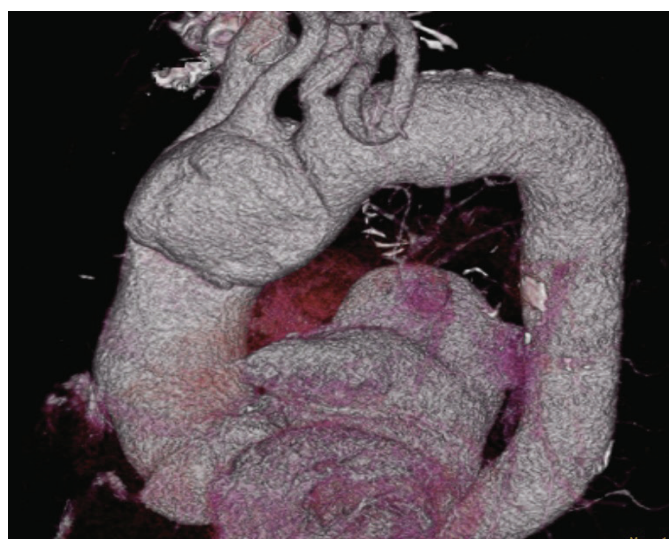


Figure 1.

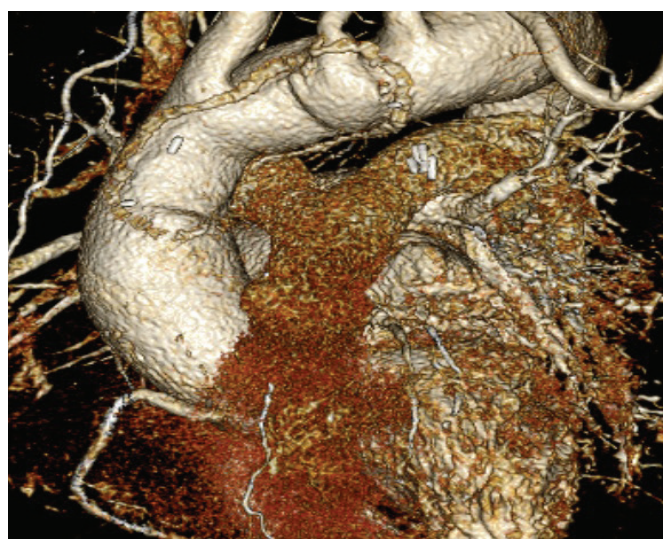

Figure 2.

References

1. Yuan SM. Cardiovascular involvement of ankylosing spondylitis: report of three cases. *Vascular*. 2009;17(6):342-54.
2. Roman MJ, Salmon JE. Cardiovascular manifestations of rheumatologic diseases. *Circulation*. 2007;116(20):2346-55.
3. Gornik HL, Creager MA. Aortitis. *Circulation* 2008;117:3039-51

Received: 24/06/2016

Accepted: 22/08/2016

Published: 15.09.2016

Disclosure and conflicts of interest:

Conflicts of interest were not reported.

Corresponding author:

Dr. Kıvanç Atılğan

Mail: kivancatilgan@gmail.com

Demirdaş E, Atılğan K., Sevuk U., Çiçekçioğlu F. Aortic aneurysm and mitral regurgitation as first manifestations of ankylosing spondylitis EJCM 2016; 04 (3): 71-72. Doi: 10.15511/ejcm.16.00371.

Infective endocarditis after tattooing in adolescent patient with ventricular septal defect

Çetin Alak¹

¹⁾ Dokuz Eylül University Faculty of Medicine, Department of Cardiology, Dr., Izmir, Turkey

Abstract

Congenital heart disease (CHD), valvular diseases and medical procedures are some of well-known predisposing factors for infective endocarditis (IE). IE after tattooing is uncommon complication comparing local infections, allergic reactions etc. But, advances made in diagnosis and treatment of CHD result an increasing adult CHD population and tattooing is also becoming more popular in adolescent and young adults. Therefore, IE after tattooing is likely to be seen more. Herein, we report a patient with ventricular septal defect who developed IE after tattooing.

Keywords: Infective endocarditis, tattooing, congenital heart disease, ventricular septal defect

Alak Ç. Infective endocarditis after tattooing in adolescent patient with ventricular septal defect.
EJCM 2016; 04 (3): 73-76. Doi: 10.15511/ejcm.16.00373.

Introduction

Infective endocarditis (IE) is a dangerous complication of body arts in patients with and without congenital heart disease (CHD).¹ Tattooing and body piercing has been becoming more popular and socially acceptable. Therefore, IE cases associated with body art continue to be reported in the literature. According to our knowledge, only three cases with CHD and IE after tattooing have been reported to date.²⁻⁴ Herein, we report a patient with ventricular septal defect (VSD) who developed IE after tattooing.

Figure 1. Image of the patient's right arm with tattoo.



Case presentation

A nineteen-year-old male patient with no prior medical history started having widespread rash a week after getting tattoo to his right arm (**Figure 1**). He was admitted to dermatology department. Although rashes tended to disappear with prednisolone, nausea, vomiting and fever episodes began. He was referred to our clinic due to hearing of serious cardiac murmur. In his detailed medical history, he denied erythema, swelling, and discharge after tattooing and intravenous drug abuse.

Physical examination revealed body temperature of 39.5°C, heart rate of 120 beats/min, blood pressure of 105/65 mmHg and IV/VI pansystolic murmur ant thrill on mesocardiac region. On laboratory tests, hemoglobin level was 9.11 g/dl, white blood cell count 21,700 (K/ μ l), platelet count 305,000 (K/ μ l), serum urea 28 mg/dl, and serum creatinine 0.93 mg/dl. Sedimentation rate was 89 mm/h and CRP was 19 mg/dl (Normal range: 0-0.3 mg/dl).

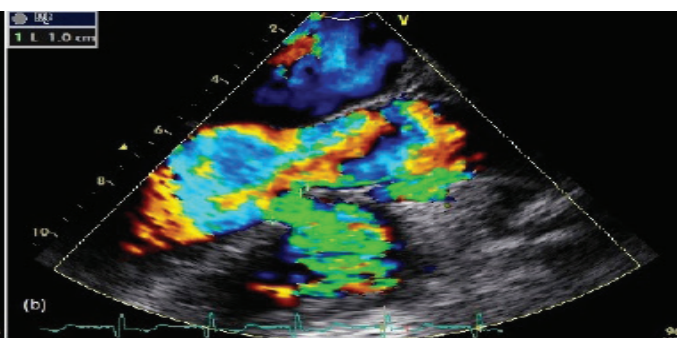
Transthoracic and transesophageal echocardiography was performed revealing mobile mass (18×6 mm) attached to right ventricular outflow track consistent with endocarditis (**Figure 2a**) and 10-mm ventricular septal defect with left to right shunt (**Figure 2b**). Qp/Qs was calculated as 1.6. Five blood cultures were collected from the patient; three samples on the first and two samples on the second day of administration to hospital. He was empirically started on cefazolin.

Blood was cultured in BACTEC (Beckton Dickinson, USA) and incubated in BACTEC FX 200 (Beckton Dickinson, USA). Identification and antibiotic sus-

Figure 2a. Transesophageal echocardiography demonstrating mobile mass (18×6 mm) attached to right ventricular outflow track.

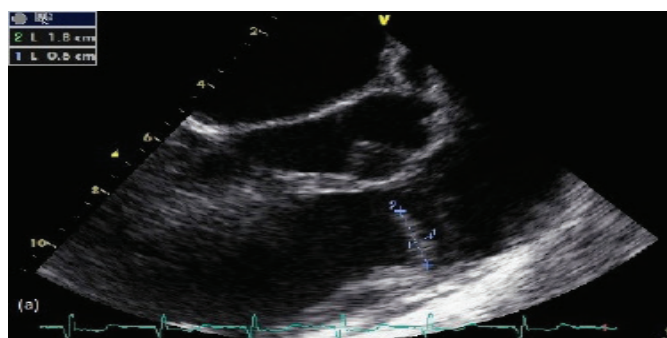

Figure 2b. Color Doppler image showing 10-mm ventricular septal defect causing turbulent flow.



ceptibilities were done by BD Phoenix 100 (Beckton Dickinson, USA). All blood cultures were positive for *Streptococcus sanguis*. Daptomycin was substituted for cefazolin. The operation was performed at non-active period after antibiotherapy. The defect was directly closed and the vegetation was excised totally. After 6-week treatment, he was discharged with no complaint.

Discussion

Infective endocarditis is still related with high mortality, despite advances in diagnostic methods, antibiotic treatment, and surgical treatment options. Lots of causative microorganisms were reported. Valvular and congenital heart diseases (CHD) are common predisposing factors for IE.⁵⁻⁷ Advances made in diagnosis and treatment of CHD result an increasing adult CHD population. Transient bacteriemia occurring after skin break can lead to IE particularly in individuals with

CHD. Tattooing is a fashionable practice involving skin breaks up to 150 times a second. It can result superficial and deep local infections, systemic infections, allergic reactions, granulomatous reactions and other skin diseases such as eczema, psoriasis etc.⁸

Although IE following tattooing remains an uncommon complication, its incidence is likely to be raised with increasing adult CHD population and popularity of tattooing. Therefore education of patients and body art professionals about good hygienic practice and wound care is vital, especially in patients with CHD.

In conclusion, non-medical procedures; such as tattooing, piercing can be a risk factor for development of IE especially in patients with structural cardiac abnormalities. Consequently, more attention should be paid to aseptic techniques during the procedures in patients with CHD.

References

1. Armstrong ML, DeBoer S, Cetta F. Infective endocarditis after body art: a review of the literature and concerns. The Journal of adolescent health : official publication of the Society for Adolescent Medicine. Sep 2008;43(3):217-225.
2. Satchithananda DK, Walsh J, Schofield PM. Bacterial endocarditis following repeated tattooing. Heart. Jan 2001;85(1):11-12.
3. Tse D, Khan S, Clarke S. Bacterial endocarditis complicating body art. International journal of cardiology. Mar 20 2009;133(1):e28-29.
4. Akkus NI, Mina GS, Fereidoon S, et al. Tattooing complicated by multi-valvular bacterial endocarditis. Herz. May 2014;39(3):349-351.
5. McKinsey DS, Ratts TE, Bisno AL. Underlying cardiac lesions in adults with infective endocarditis. The changing spectrum. The American journal of medicine. Apr 1987;82(4):681-688.
6. Gersony WM, Hayes CJ, Driscoll DJ, et al. Bacterial endocarditis in patients with aortic stenosis, pulmonary stenosis, or ventricular septal defect. Circulation. Feb 1993;87(2 Suppl):1121-126.
7. Agca N, Peker T, Ari H, et al. Infective endocarditis: a tertiary referral centre experience from Turkey. International journal of clinical and experimental medicine. 2015;8(8):13962-13968.
8. Khunger N, Molpariya A, Khunger A. Complications of Tattoos and Tattoo Removal: Stop and Think Before you ink. Journal of cutaneous and aesthetic surgery. Jan-Mar 2015;8(1):30-36.

Received: 21/03/2016

Accepted: 14/08/2016

Published: 15.09.2016

Disclosure and conflicts of interest:

Conflicts of interest were not reported.

Corresponding author:

Dr. Çetin Alak

Mail: cetinalak@mynet.com

Alak Ç. Infective endocarditis after tattooing in adolescent patient with ventricular septal defect. EJCM 2016; 04 (3): 73-76. Doi: 10.15511/ejem.16.00373.

E-Journal of Cardiovascular Medicine welcomes scientific contributions in the field of cardiovascular and thoracic surgery - all aspects of surgery of the heart, vessels and the chest in various article types: new ideas, brief communications, work in progress, follow-up studies, original articles, best evidence topics, case reports, reports on unexpected results etc. All manuscripts shall be reviewed by the Editor-in-Chief, Associate Editors, Invited Referees and a Statistician when appropriate. If accepted, articles will be posted online and opened up for discussion. Acceptance criteria are based on the originality, significance, and validity of the material presented.

All material to be considered for publication in E-Journal of Cardiovascular Medicine should be submitted in electronic form via the journal's online submission system. (<http://my.ejmanager.com/ejcm/>)

A cover letter should be enclosed to all new manuscripts (to be filled in online), specifying the name of the journal and the type of paper, and including the following statements:

- The manuscript should not be previously published in print or electronic form and is not under consideration by another publication.
- All authors should contribute to the content of the article.
- All authors should read and approve the submission of the manuscript to ICVTS.
- Subject to acceptance, authors will sign an exclusive license to publish.
- No ethical problem or conflict of interest should exist.

If your first language is not English, we recommend that you consult an English language editing service to ensure that the academic content of your paper is fully understood by journal editors and reviewers. Language editing does not guarantee that your manuscript will be accepted for publication.

Manuscripts should be prepared using a word-processing package (save in .doc, .docx or .rtf format). The font type and font size should preferably be Arial or Times New Roman 11 points. The manuscript should be double-spaced and should include line and page numbers. The lines of the reference list do not need to be numbered; include a section break before.

Manuscripts should be organized as follows:

(a) Title page; (b) Abstract and Key words; (c) Text with the following sections (not applicable for article types with unstructured abstracts): Introduction, Materials and Methods, Results, Discussion, Acknowledgement (optional), Funding statement, Conflict of interest statement, (d) Figure (and Video) legends; (e) Tables; (f) References.

Title page (1st page): Title: should be brief and descriptive (100 characters) - no abbreviations are allowed, even if well known.

Authors: list all authors by full first name, initial of or full middle name and family name. Qualifications are not required. Ensure the author names correspond (in spelling and order of appearance) with the metadata of the system

Institution(s): include the name of all institutions with the location

(department, institution, city, country) to which the work should be attributed (in English). Use superscript numbers to connect authors and their department or institution.

Corresponding author: The full name, full postal address, telephone/fax numbers and the e-mail address should be typed at the bottom of the title page.

Meeting presentation: If the manuscript was (or will be) presented at a meeting, include the meeting name, venue, and the date on which it was (or will be) read; also indicate if you have submitted an Abstract of this manuscript for the EACTS or ESTS annual meeting and whether it has been accepted (if known).

Word count: The total number of words of the whole article (including title page, abstract, main text, legends, tables and references) must be specified on the title page.

Abstract (2nd page): An abstract should be a concise summary of the manuscript. Reference citations are not allowed. The abstract should be factual and free of abbreviations, except for SI units of measurement.

Keywords: Following the abstract, 3-6 keywords should be given for subject indexing.

Introduction: Should state the purpose of the investigation and give a short review of pertinent literature.

Materials and methods: Should be described in detail with appropriate information about patients or experimental animals. Use of abbreviations renders the text difficult to read; abbreviations should be limited to SI units of measurement and to those most commonly used, e.g. VSD, ASD, CABG (abbreviations should not be included in headings and extensions should be included at first mention).

Results: Results should be reported concisely and regarded as an important part of the manuscript. They should be presented either in tables and figures, and briefly commented on in the text, or in the text alone. Repetition of results should be avoided!

Discussion: The discussion is an interpretation of the results and their significance with reference to pertinent work by other authors. It should be clear and concise.

Acknowledgement: Acknowledgements and details of non-financial support must be included at the end of the text before the references. Personal acknowledgements should precede those of institutions or agencies.

Tables: All tables must be included in the manuscript file, should start on separate pages and be accompanied by a title, and footnotes where necessary. The tables should be numbered consecutively using Arabic numerals. Units in which results are expressed should be given in parentheses at the top of each column and not repeated in each line of the table.

References: Authors are responsible for checking the accuracy of all references. If you use EndNote or Reference Manager to facilitate referencing citations (not required for submission), this journal's style is available for use. References should be numbered in order of appearance in the text (in Arabic numerals in parentheses) and must be listed numerically in the reference list. Journal titles and author initials should be properly abbreviated and punctuated.

GENERAL RULES

Files should be prepared as a Word document using font size 12 Times New Roman characters, double-spaced and with 2.5 cm margins on each side, top and bottom. Only standard abbreviations should be used; other shortened phrases should be indicated in parentheses as used in the text. Generic or chemical names of drugs should be used instead of trade names.

ETHICAL ISSUES

Publishing responsibilities of authors and Ethics

The publication of an article in a peer-reviewed journal is an essential building block in the development of a coherent and respected network of knowledge. It is a direct reflection of the quality of work of the author and the institutions that support them. Peer-reviewed articles support and embody the scientific method. It is therefore important to agree upon standards of expected ethical behavior.

Reporting standards

Authors of reports of original research should present an accurate account of the work performed as well as an objective discussion of its significance. Underlying data should be represented accurately in the paper. A paper should contain sufficient detail and references to permit others to replicate the work. Fraudulent or knowingly inaccurate statements constitute unethical behavior and are unacceptable. Review and professional publication articles should also be accurate and objective, and editorial 'opinion' works should be identified as such.

Hazards and human or animal subjects

If the work involves chemicals, procedures or equipment that have any unusual hazards inherent in their use, the author must clearly identify these in the manuscript. If the work involves the use of animal or human subjects, the author should ensure that the manuscript contains a statement that all procedures were performed in compliance with relevant laws and institutional guidelines and that the appropriate institutional committee(s) has approved them. Authors should include a statement in the manuscript that informed consent was obtained for experimentation with human subjects. The privacy rights of human subjects must always be observed.

Use of patient images or case details

Studies on patients or volunteers require ethics committee approval and informed consent, which should be documented in the paper. Appropriate consents, permissions and releases must be obtained where an author wishes to include case details or other personal information or images of patients and any other individuals in publication. Written consents must be retained by the author and copies of the consents or evidence that such consents have been obtained must be provided to us on request. Particular care should be taken with obtaining consent where children are concerned (in particular where a child has special needs or learning disabilities), where an individual's head or face appears, or where reference is made to an individual's name or other personal details.

Originality and plagiarism

The authors should ensure that they have written entirely original works, and if the authors have used the work and/or words of

others, that this has been appropriately cited or quoted. Plagiarism takes many forms, from 'passing off' another's paper as the author's own paper, to copying or paraphrasing substantial parts of another's paper (without attribution), to claiming results from research conducted by others. Plagiarism in all its forms constitutes unethical publishing behavior and is unacceptable.

Data access and retention

Authors may be asked to provide the raw data in connection with a paper for editorial review, and should be prepared to provide public access to such data (consistent with the ALPSP-STM Statement on Data and Databases), if practicable, and should in any event be prepared to retain such data for a reasonable time after publication.

Multiple, redundant or concurrent publication

An author should not in general publish manuscripts describing essentially the same research in more than one journal or primary publication. Submitting the same manuscript to more than one journal concurrently constitutes unethical publishing behavior and is unacceptable. In general, an author should not submit for consideration in another journal a previously published paper. Publication of some kinds of articles (e.g. clinical guidelines, translations) in more than one journal is sometimes justifiable, provided certain conditions are met. The authors and editors of the journals concerned must agree to the secondary publication, which must reflect the same data and interpretation of the primary document. The primary reference must be cited in the secondary publication.

Acknowledgement of sources

Proper acknowledgment of the work of others must always be given. Authors should cite publications that have been influential in determining the nature of the reported work. Information obtained privately, as in conversation, correspondence, or discussion with third parties, must not be used or reported without explicit, written permission from the source. Information obtained in the course of confidential services, such as refereeing manuscripts or grant applications, must not be used without the explicit written permission of the author of the work involved in those services.

Fundamental errors in published works

When an author discovers a significant error or inaccuracy in his/her own published work, it is the author's obligation to promptly notify the journal editor or publisher and cooperate with the editor to retract or correct the paper. If the editor or the publisher learns from a third party that a published work contains a significant error, it is the obligation of the author to promptly retract or correct the paper or provide evidence to the editor of the correctness of the original paper.

Authorship of the paper

Authorship should be limited to those who have made a significant contribution to the conception, design, execution, or interpretation of the reported study. All those who have made significant

contributions should be listed as co-authors. Where there are others who have participated in certain substantive aspects of the research project, they should be acknowledged or listed as contributors. The corresponding author should ensure that all appropriate co-authors and no inappropriate co-authors are included on the paper, and that all co-authors have seen and approved the final version of the paper and have agreed to its submission for publication.

Changes to authorship

This policy concerns the addition, deletion, or rearrangement of author names in the authorship of accepted manuscripts. Before the accepted manuscript is published in an online issue:

Requests to add or remove an author, or to rearrange the author names, must be sent to the Journal Manager by the corresponding author of the accepted manuscript, and must include:

The reason the name should be added or removed, or the author names rearranged

Written confirmation (e-mail, fax, letter) from all authors that they agree with the addition, removal or rearrangement. In the case of addition or removal of authors, this includes confirmation from the author being added or removed

Requests that are not sent by the corresponding author will be forwarded by the Journal Manager to the corresponding author, who must follow the procedure described above.

Note that:

- Journal Managers will inform the Journal Editors of any such requests
- Publication of the accepted manuscript in an online issue is suspended until authorship has been agreed
- After the accepted manuscript has been published in an online issue:

Any requests to add, delete or rearrange author names in an article published in an online issue will follow the same policies as noted above and may result in a corrigendum.

TYPES OF PAPERS

Original Articles

Original articles should consist of sections titled as “Abstract, Introduction, Materials and Methods, Results, Discussion and Conclusion”. For information about the abstract, refer to ‘Manuscript Formatting’ section.

The Introduction section of the manuscript should clearly state the purpose of the manuscript and include a brief summary of the most relevant national and international literature stating the main purposes and research question of the study. Contradictory aspects of the research, if present, should be mentioned. The expected contribution of this study to family medicine and practice should be highlighted.

The Materials and Methods section should describe the study population and the study design, with adequate information on the

techniques, materials and methods used. The section should include information of the study type, population, sample, sample size and selection of the sample. Validity and reliability of scales and questionnaires used also should be referred to. A clear description of the statistical methods should also be given.

The Results section should include a detailed report on the findings of the study. All figures, tables and illustrations should be used in this section. Results should be presented either as text or figures and/or tables and not be replicated.

The Discussion section of the study should emphasize the importance of the results and compare them with the results of other authors with relevant citations from the most recent literature. Study limitations and strengths should be specified. Suggestions for further studies in this area should be added.

The Conclusion should include the main conclusions based on the results of the research, emphasize the contributions of the study to family practice and propose original suggestions. A brief revision of all the results and the discussion should be avoided.

Original articles excluding case reports and systematic reviews should not exceed 3000 words excluding the abstract, references and tables. Case reports should not exceed 1000 words excluding the abstract, references and tables. There are no restrictions for systematic reviews.

Short Reports

Short Reports are accepted when the research topic, aim and results of the study are limited in scope and in cases that do not require writing a full original article. Short Reports can be described as a summarized version that have been prepared according to the structure of research articles. Publishing an article as a short report does not reflect a lower quality. The same rules as relevant to original articles apply to preparing a short report, but structured abstracts are not mandatory references and tables should not exceed 6 and 2 in number, respectively. Abstracts should not exceed 100 words and the text should be restricted to a maximum of 1000 words.

Reviews

Reviews are evidence-based articles about a specific topic using relevant citations from the most recent literature with the authors’ conclusions on this subject. The author is expected to have conducted research on the subject and to have experience in order to discuss and analyze the subject. There is no obligation to follow a particular format and may contain subtitles depending on the subject. The text should not exceed 4000 words excluding the title, abstracts, references and tables. E Journal of Cardiovascular Medicine, only publishes review articles solicited by the editors.

Letters to Editor and Comments

Letters to the editor or comments can be sent to provide commentary and analysis concerning an article published in the journal, to give information about ongoing research, to provide informa-

tion in cardiology and cardiovascular-vascular-endovascular surgery, cardio-metabolic and vascular sciences. Letters to the editor or comments may include an optional title, tables and references. These articles should not exceed 1000 words.

What Would You Do?

These are brief articles discussing cases and situations encountered in cardiology and cardiovascular surgery with a biopsychosocial approach. If necessary, photographs (with permission from the patient/owner) may be added. Sections should consist of a title, case report, discussion, questions and answers. Brief comments can be sent to provide commentary on previous articles and case reports written by other authors. Comments should include the number of the journal the article was published in. The text should not exceed 1000 words.

International Reprints

Translations of important documents, declarations and guidelines prepared by international organizations in the field of cardiology and cardiovascular surgery, may be published in the journal. Presubmission Inquiry to the Editorial Board of the Journal before submitting the article is recommended. It is the translator's responsibility to obtain permission from the owner of the original manuscript for publication and translation.

News

These articles focus on advances and innovations in clinical topics relevant to cardiology and cardiovascular surgery. There is no obligation to follow a particular format. The text should be limited to 1000 words.

Editorials

Editorials usually provide information about the editorial policy of E Journal of Cardiovascular Medicine, give commentary and feedback on articles published in the journal, draw attention to topics of current interest and give information related to and discuss the development of cardiology and cardiovascular surgery in the world. They are mainly written by the members of the Editorial Board. Editorials are limited to 2000 words with some exceptions and may include a title and references when necessary.

MANUSCRIPT FORMATTING

Manuscripts should be designed in the following order:

Title page

Abstract

Main text

References

Tables, figures and illustrations

Title Page

The title page of the manuscript should include: The title, first

and last names of each author. Complete affiliation and title for each author, with the name of department (s) and institution (s) to which the work should be attributed.

The corresponding author should be clearly identified with name, address, telephone- facsimile number and email address for correspondence about the manuscript. Authors should clearly indicate if the article has previously been presented at a congress or scientific meeting. The title should be concise and informative without abbreviations and not exceed 10 words.

Abstract

Abstracts should be exact in English, with a minimum of 150 and maximum of 350 words. Abstracts of original research articles should be structured under subheadings as follows: objectives, methods, results and conclusion. A maximum of 3 key words should be added to English abstracts.

Text

The text contains the rest of the manuscript. It is structured differently according to the type of manuscript (original research article, review, etc.). For example, original research articles should consist of aim and objectives, methods, results, discussion and conclusion.

References

References should be cited in consecutive numerical order as first mentioned in the text and designated by the reference number in parentheses. If the number of authors for the reference is more than 6 authors, list the first three authors and add "et al".

Journal names should be abbreviated as used in Index Medicus. References should be cited in the Vancouver style. For detailed information please visit the relevant link

Examples:

For research articles follow the example below:

– Verschuren WM, Jacobs DR, Bloemberg BP, et al. Serum total cholesterol and long-term coronary heart disease mortality. JAMA 1995; 274(2): 131–6.

For book chapters follow the example below:

– Rakel RE. The family physician. In: Rakel RE, editor. Text-book of family practice. 5th ed. Philadelphia: W.B. Saunders; 1995. p. 3-19.

For web pages follow the example below:

– Guidance for clinicians. An International Benchmarking Study. <http://www.who.int/topics/surgery/> accessed: 29/09/2002.

Tables and Figures

Legends should take place on the top of the page for tables, and bottom of the page for figures and placed on separate pages. Explain all nonstandard abbreviations in footnotes.



E Journal of Cardiovascular Medicine
is a global e-journal targeting articles on:

- clinical cardiology,
- interventional cardiology,
- arrhythmia,
- cardiovascular surgery,
- vascular & endovascular surgery,
- vascular biology